

Multidisciplinary investigation of stranded harbor porpoises (*Phocoena phocoena*) in Washington State with an assessment of acoustic trauma as a contributory factor (2 May – 2 June 2003)



S.A. Norman, S. Raverty, B. McLellan, A. Pabst, D. Ketten, M. Fleetwood, J.K. Gaydos, B. Norberg, L. Barre, T. Cox, B. Hanson, and S. Jeffries



U.S. Department of Commerce
National Oceanic and Atmospheric Administration
National Marine Fisheries Service

NOAA Technical Memorandum NMFS-NWR-34
October 2004

Multidisciplinary investigation of stranded harbor porpoises (*Phocoena phocoena*) in Washington State with an assessment of acoustic trauma as a contributory factor (2 May – 2 June 2003)

S.A. Norman, S. Raverty, B. McLellan, A. Pabst, D. Ketten, M. Fleetwood, J.K. Gaydos, B. Norberg, L. Barre, T. Cox, B. Hanson, and S. Jeffries

National Marine Fisheries Service – Northwest Region

**NOAA Technical Memorandum NMFS-NWR-34
October 2004**



U.S. Department of Commerce
Donald L. Evans, Secretary

National Oceanic and Atmospheric Administration
Vice Admiral Conrad C. Lautenbacher, Jr., USN (Ret.)
Under Secretary for Oceans and Atmosphere

National Marine Fisheries Service
William T. Hogarth, Assistant Administrator for Fisheries

Suggested citation:

Norman, S.A., Raverty, S., McLellan, B., Pabst, A., Ketten, D., Fleetwood, M., Gaydos, J.K., Norberg, B., Barre, L., Cox, T., Hanson, B., and Jeffries, S. 2004. Multidisciplinary investigation of stranded harbor porpoises (*Phocoena phocoena*) in Washington State with an assessment of acoustic trauma as a contributory factor (2 May – 2 June 2003). U.S. Dep. Commerce, NOAA Tech. Memo. NMFS-NWR-34, 120 p.

A copy of this report may be obtained from:

**National Marine Fisheries Service
Northwest Region
7600 Sand Point Way NE, Bldg. 1
Seattle, WA 98115**

**Office of Science and Technology
NMFS, NOAA
1315 East-West Highway, F/ST
Silver Spring, MD 20910**

Or online at:

http://www.nwr.noaa.gov/mmammals/NWR-34_porp_rep.htm

Abstract

Observations of altered behavior of marine mammals in the area of mid-range sonar use by the naval vessel *USS SHOUP* in the eastern Strait of Juan de Fuca and Haro Strait on 5 May 2003, prompted the National Marine Fisheries Service (NMFS) to conduct an in-depth investigation on the causes of harbor porpoise strandings. Fifteen stranded harbor porpoises were reported during the period of 2 May 2003 to 2 June 2003, an abnormally high number when compared to the average stranding rate of 6 per year recorded over the previous decade. Eleven of the stranded harbor porpoises were collected for this investigation.

NMFS assembled a multidisciplinary team to conduct extensive classical forensic necropsy examinations on the 11 specimens, followed by laboratory diagnostic and histological analyses and complemented by high resolution computerized tomography (CT) scans. Samples were taken for a variety of analyses including disease screening, parasitology, chemical contaminant and lipid analyses, aging studies, prey identification and domoic acid analysis. The gross and microscopic findings from the necropsy examinations, laboratory results, and the analysis of the CT image data for each specimen are provided. Information on the discovery and collection of the stranded porpoises, and a comparison of this with porpoise strandings over the previous ten years is also included in this report.

Over 70 percent of the specimens were in moderate to advanced states of decomposition which made interpretation of the cause of death difficult. The cause of death was determined for five of the 11 porpoises examined by the multidisciplinary team. Of these five animals, two were found to have suffered blunt force trauma, while illness (peritonitis, salmonellosis, pneumonia) was implicated in the remaining three cases. No cause of death could be determined for the remaining six animals. The examinations did not reveal definitive signs of acoustic trauma in any of the porpoises examined. The multidisciplinary team noted that lesions consistent with acoustic trauma can be difficult to interpret or obscured, especially in animals in advanced postmortem decomposition. Because many of the carcasses investigated were in moderate to poor condition, the possibility of acoustic trauma from exposure to mid-range sonar as a contributory factor in the mortality of any of the porpoises could not be ruled out.

TABLE OF CONTENTS

Abstract	iii
Introduction	1
Materials and Methods	2
Results	5
Summary of post mortem examinations and laboratory results.....	46
Discussion	50
Conclusion.....	55
Acknowledgments	55
Literature Cited.....	56
Glossary.....	59

FIGURES

Figure 1. Reported porpoise strandings in Washington State 2 May – 2 June 2003.....	62
--	----

TABLES

Table 1. Reported harbor porpoise strandings in Washington State - 2 May-2 June 2003.	63
Table 2. Freezer specifications used to store and transport porpoises prior to necropsy.	64
Table 3. Body composition of harbor porpoises examined during the necropsy session.....	65
Table 4. Summary of organochlorine concentrations in the blubber.	66
Table 5. Bacteriology results for harbor porpoise specimens.	67
Table 6. Trace mineral and vitamin A analyses of liver, kidney and vitreous humor.....	69
Table 7. Summary of post mortem findings of examined harbor porpoises	70
Table 8. Summary table of CT scan results	71
Table 9. Spatial distribution of harbor porpoise strandings in Washington State - 1992-2003.....	51
Table 10. Harbor porpoise stranding events in Washington State - 1992-2003 (April-June).	52

APPENDICES

Appendix A. Sample Level A stranding form and completed forms for this investigation.....	74
Appendix B. Level A stranding forms for stranded harbor porpoises 2 May – 2 June 2003.....	75
Appendix C. Porpoise investigation team members.....	94
Appendix D. CT Imaging reports	98
Appendix E. Phocoenid strandings in British Columbia, Canada (April-May 2003).....	114
Appendix F. List of harbor porpoise stranding events in Washington State 1992-2002.	115
Appendix G. Marine mammal stranding events in Washington St. (1 April – 30 June 2003). ..	119

INTRODUCTION

On 5 May 2003 the naval vessel *USS SHOUP* operated its tactical sonar system (AN/SQS-53C) during a military exercise, while transiting the eastern Strait of Juan de Fuca and Haro Strait between Vancouver Island (Canada) and San Juan Island (US). NMFS received reports from witnesses who observed behavioral changes in several species of marine mammals on 5 May. Within several days of the exercise, a number of harbor porpoise (*Phocoena phocoena*) carcasses were found beach cast around the eastern Strait of Juan de Fuca. The reports of behavioral changes by whales during the exercise and the appearance of the dead porpoises on shore prompted NMFS to initiate an investigation to assess the cause of the porpoise strandings, including an assessment of acoustic trauma as a possible contributing factor. The activities of the *USS SHOUP* and the details of the 5 May 2003 sonar exercise are described in a report released by the U.S. Navy on 9 February 2004 (United States Navy, 2004).

To assist with NOAA's investigation, members of the Northwest Marine Mammal Stranding Network (Stranding Network) initiated efforts to respond rapidly to porpoise stranding reports and to collect carcasses from the beach. During a one month period from 2 May 2003 to 2 June 2003, the Stranding Network received a total of 15 reports of stranded harbor porpoises found dead, on the shore or floating, in the Strait of Juan de Fuca, along the outer coast, and in the vicinity of Whidbey Island and San Juan Island, Washington State (Figure 1; Table 1). The Stranding Network recovered three of the 11 porpoises examined in this investigation prior to 5 May, three on 5 and 6 May and the remaining five during the subsequent weeks. NMFS also received video footage labeled "porpoises and Navy Sonar 25 April 03". In light of these reports, all carcasses collected were thoroughly examined for potential links to sonar or other acoustic activities, including carcasses collected prior to 5 May. Basic information (Level A data; Appendix A) was collected from all 15 strandings (Appendix B). Specimen parts (whole bodies or heads) were collected from 11 of the stranded harbor porpoises. The collected specimens were frozen for subsequent close examination in the laboratory to investigate the causes of death and determine whether physical evidence of sonar or acoustic related injuries was present. In addition to recordings made on 5 May, hydrophone operators submitted audio files of sounds they identified as sonar, dated 9 December 2002, 24 April 2003 and 4 May 2003.

The observations on 5 May were highly publicized and resulted in heightened public concern that naval sonar activity may have contributed to the porpoise deaths. NMFS met with representatives from the Navy to discuss the whale observations, the porpoise strandings, the activities of the *USS SHOUP*, and hydrophone recordings received. Specifically, witnesses reported seeing avoidance behaviors by southern resident killer whales (*Orcinus orca*) and a minke whale (*Balaenoptera acutorostrata*) "porpoising" from the area as the vessel approached. Researchers operating hydrophones in Haro Strait recorded acoustic signals identified as sonar. NMFS received additional reports from witnesses that the sonar sound was audible above water.

NMFS assembled a multidisciplinary team of scientists and experts to conduct forensic post mortem examinations and to analyze the data for evidence of acoustic impacts

(Appendix C). The team from federal and State agencies, universities and research institutions included marine biologists, veterinarians, veterinary pathologists, research scientists and anatomists specializing in neuroanatomy, life history and trauma. NMFS contracted a local medical imaging company to obtain high resolution CT scan images from the carcasses.

This report represents the gross and microscopic findings from the necropsy examinations on each of the 11 specimens, laboratory analyses, and the analysis of the CT images data for each specimen scanned. Information on the discovery and collection of the stranded porpoises, and a comparison of this with porpoise strandings over the previous eleven years, is also presented. A preliminary report on this porpoise investigation was released by NMFS on 9 February 2004 for scientific review. Comments received were distributed to the team for discussion. The preliminary report was revised to address the comments, resulting in this final report.

MATERIALS AND METHODS

Network participants investigated 15 reports of individual harbor porpoise strandings and collected whole carcasses or heads from 11 porpoises that could be located based on information from initial sighting reports. Responders noted body conditions ranging from fresh dead to advanced decomposition when the specimens were collected in the field and obtained photographs of some carcasses. Attempts were made to verify initial carcass condition as described by the individual(s) who initially reported the stranding. The elapsed time from earliest known report date to examination/collection by a stranding network participant ranged from hours to several days. Therefore, carcass condition codes on the date of initial observation did not always correlate with the condition code at time of necropsy. Level A data were collected, but additional detailed information (*e.g.*, time of day and position of animal) at initial observation was not documented in a standardized fashion due to varied individuals responding to the strandings.

Upon collection, specimens (carcasses/heads) were assigned a field identification number (Field ID) by the stranding network responder, tagged and transported either directly to Seattle or to local freezers where they were held frozen (-20° F degree) pending later processing and necropsy (see Table 2 for listing of freezer types and specifications). Frozen specimens were transported from field locations and to/from the scanning facility in a truck mounted chest freezer to avoid thawing. Ultimately all specimens were transferred to and held at the NMFS/Alaska Fisheries Science Center/National Marine Mammal Laboratory (NMML) walk-in freezer for examination. This freezer was the only one with available space at NOAA. As each stranding report was received by NMFS, it was assigned a unique NMFS Registration Number. Registration Numbers do not always correspond to the chronological order in which animals have stranded, as these numbers are assigned when the Level A Stranding Reports arrive at the NMFS office in Seattle. A new tag with the NMFS Registration Number was attached to each carcass, and this number became the sole ID number used to identify specimens throughout the imaging and necropsy procedures (Table 1). Once the carcasses were

frozen, NMFS staff avoided thawing and/or re-freezing during subsequent handling until the specimens were prepared for post mortem examination.

The multidisciplinary team identified appropriate equipment and determined the protocols for conducting high resolution computerized tomography (CT scanning) and necropsies of the carcasses. In addition, a number of scientists involved in ongoing porpoise studies were contacted regarding protocols for collecting samples for their studies. A blind study approach was implemented during scanning, necropsy examination and data collection. The original Field ID tag remained with the carcass, but was covered by a taped bag so that the investigative team had no access to date and locality information. This helped prevent bias by team members during their investigation regarding locality and timing of strandings in relation to the *USS SHOUP* activities.

Six whole carcasses and two heads were selected by NMFS for scanning based on the following criteria: (1) date of stranding; (2) locality of stranding; and (3) carcass condition. The specimens with the best carcass condition were selected for scanning and represented a range of dates before, during and after 5 May. The selected specimens were transported in a truck mounted chest freezer to a local medical imaging facility, scanned on 20 July 2003 and returned to the NMML freezer. Scans were obtained at the scanning facility and formatted as a series as transaxial head and body images in both soft and bone windows using a spiral scan protocol. All scans were conducted with the body in a prone position, rostrum first. Images provided had variable slice thicknesses of 1-8 mm in bone and soft tissue protocols. The majority of scans were performed at 120 kV/250 MA. At the time of analyses, reformatted images were also produced, comprising soft tissue and bony windows of the head and body with expanded views of the brain and ear in transaxial, sagittal and coronal planes to optimize ear and brain detail from the available images. Three-dimensional reconstructions of some head structures were also produced (see Figures 21 and 32).

Following the scanning, carcasses were sorted and selected for thawing prior to necropsy based upon carcass condition. The “freshest” appearing carcasses were thawed for examination first. It was not always possible to standardize the position (*e.g.* same side down every time) of the carcasses during thawing; however, an attempt was made to try and consistently necropsy each carcass with the right side of the animal facing down against the table top.

Gross examination

A total of 10 porpoises were necropsied (the 11th specimen-a head only [03NWR05003]-was scanned, but determined to be too decomposed to provide useful data or samples during necropsy). Two to four carcasses at a time were thawed overnight in an aluminum casket filled with cold tap water. Data were collected and recorded on the Specimen Record, Evaluation of Human Interaction, Phocoena Mass Dissection, Cetacean Body Surface Area, and Blubber Thickness/Mass data sheets for general body examination and the Marine Mammal Sensory Group Cetacean Necropsy Report for examination of heads

and auditory structures. Collection of samples was tracked on a separate data sheet. All tissue and fluid samples that could be analyzed were obtained.

Comprehensive classical forensic and necropsy examinations were performed on each animal, including screening for pathogens, disease states and traumatic injury. On 22 July, the first two carcasses were removed from the thawing water and post mortem examinations were conducted according to prearranged protocols. On 23 July, necropsies were performed on four carcasses. On 24 July, the remaining four carcasses were necropsied. The severed head of specimen number 03NWR05008 was necropsied on 23 July. Descriptions of carcass condition (freshness of the carcass – Table 1) and body condition (nutritional status of the animal – Table 3) are described for each animal examined. Carcass condition codes were assigned based upon the Smithsonian Institution's codes for carcass condition: live (Code 1); fresh/good condition (Code 2); fair/moderately decomposed (Code 3); and poor/advanced decomposition (Code 4) (Geraci and Lounsbury, 1993). Each score is subjective, and discrepancies between codes at time of stranding response and at time of necropsy can occur because of (1) individual differences in that scoring process and (2) the difference in condition between the inside and the outside of the carcass. Post mortem scavenging, freeze artifact and autolysis hindered gross and microscopic tissue analysis of most specimens. Some protocols for data collection and sampling were conducted only on specimens of sufficiently high quality carcass condition.

Histopathology

During the necropsy examination, entire organs or parts were removed from the carcass to a clean area for examination. Tissues and samples for diagnostics and histology were collected according to standard necropsy protocols, fixed/preserved for analysis and distributed to labs under MMPA Permit Number 932-1489 and CITES Permit 3US020950/9. Brains were extracted and examined. Only those of sufficient quality were sampled for histopathology.

Age determination

Teeth were extracted from each specimen for age determination by sectioning and counting of growth layer groups (to be performed at NMML).

Blubber Analysis

Full-thickness blubber samples were taken for chemical contaminant and lipid analyses using gas chromatography/mass spectrometry (GC/MS) for a wide suite of persistent organic pollutants (POP), including PCB congeners, DDTs, hexachlorobenzene and chlordane (Table 4). POPs were extracted from blubber samples using an accelerated solvent extractor (ASE) (Sloan *et al.*, in prep). Lipid concentrations of the blubber samples were determined gravimetrically by measuring total non-volatile extractable material (reported as percent total lipids) (Sloan *et al.*, in press).

Other analyses

Other analyses included polymerase chain reaction (PCR) for Morbillivirus, *Brucella* and *Mycoplasma*, fecal floatation and sedimentation examination for parasitology, domoic

acid analysis of intestinal contents, stomach prey species analysis, aerobic bacterial cultures (Table 5), analyses of vitreous for blood urea nitrogen (BUN), calcium, phosphorous and magnesium and trace mineral analyses and vitamin A of liver and kidney (Table 6). As with samples for bacteriology, the suitability of samples for virus isolation was directly related to their quality and the freshness of the carcass. Viral culture was attempted in all specimens examined.

Photography

Photographs were taken at the time of carcass discovery by several different responders or volunteers. In addition, photographs were taken by several necropsy team members as directed by the individual conducting the examination at a given station. Several different research protocols were addressed simultaneously and some protocols had a standard photo format while others did not. Photographs were also taken to supplement the gross notes by examiners.

RESULTS

All animals had some degree of congestion, or red discoloration of the meninges, calvarium or cerebral surface, and in some cases of all abdominal tissues. This staining was attributed to postmortem autolysis and repeated freeze-thaw effects. This artifact hampered all gross and histological evaluation. Based on standardized carcass decomposition categories for the U.S. National Stranding Network (Geraci and Lounsbury, 1993), three porpoises were Code 2 (fresh dead), six were Code 3 (moderate decomposition) and the rest in Code 4 (advanced decomposition) at the time of necropsy. Individual cases are presented here in chronological order of stranding and not by sequential NMFS Registration Number. For each animal, comprehensive body composition data are listed in Table 3. Skeletal remains were retained for further study and tissue samples were archived at the Armed Forces Institute of Pathology and the Animal Health Centre in Abbotsford, B.C., Canada.

03NWR05001

History

This harbor porpoise was discovered dead floating off of Neck Point on Shaw Island (Figure 1) on 2 May 2003, collected and transferred to the University of Washington/Friday Harbor Lab (UWFHL) freezer on San Juan Island. The carcass was subsequently transferred to the NOAA/National Marine Mammal (NMML-32) freezer on 2 July 2003. No photograph of this animal at stranding was available.

Gross Findings

An immature 136 cm total length, 39 kg female harbor porpoise (*Phocoena phocoena*) was presented dead, 24 July 2003, in good body and fair post mortem condition. Throughout the flanks, there was extensive scavenger damage with no evidence of human interaction. Within the blubber and hypodermis of the mid-dorsal region of the melon, rostradorsal quadrant of the left eye and right mandibular fat pads, there were multiple variably sized dark red foci. Multiple superficial contact abrasions and lacerations were noted in the skin above the left eye and lower lip.



Figure 2 – Right lateral photograph of the head of porpoise 03NWR05001 at time of necropsy (24 July 2003) (Photo: B. Hanson).

The ventral fascial musculature and blubber were degraded. The oral cavity and nares contained a moderate amount of dark red, serous fluid and the larynx appeared normal.

Nervous system: In the central nervous system, a small amount of clotted blood surrounded the basioccipital region, left inferior temporal area and cervical spinal cord. The cerebral meninges were diffusely dark red and there was a moderate amount of dark red fluid beneath the pia and dura mater. Within the peribullar space of the right ear, there was an extensive accumulation of dark red gelatinous material (clotted blood).

Respiratory System: Diffusely, the lungs were dark red, moist and glistening (congestion), with a small amount of stable red foam within the trachea and bronchi. Widely dispersed throughout the pulmonary parenchyma, there were a few 1mm white calcified parasitic nodules.

Digestive system: The pancreas was dull brown to red with mild periductular fibrosis.

There were no overt lesions within the cardiovascular, endocrine, hemolymphatic, urogenital or musculoskeletal systems.

CT Findings

Cranial, thoracic and abdominal images were analyzed.

Cranial soft tissues: All soft tissues of the head were in relatively poor condition with some separation of tissue layers and multiple air pockets. The fatty layers on the right side of the head were noticeably degenerated. The soft walled narial passages were poorly defined and collapsed, but the sinuses were normal with good pneumatization.

Intracranial/brain: All skull features were normal and the brain was intact. There were extensive regions of extravasated fluid with an HU rating of 27-40 compatible with blood in the skull base and basioccipital regions with minor accumulations in the temporal areas. Cranial scans suggested broad post mortem degenerative changes with poor preservation of most structures. The intracranial spaces had moderate to extensive areas of fluid accumulation, consistent with post mortem seepage and dependent pooling of blood. There were no well-defined areas of hemorrhage, but due to poor tissue quality, it was not possible to differentiate pre vs. post mortem blood deposits. A small area in the mid-melon region appeared to be contused. The mandibular structures and head musculature were largely autolyzed and poorly preserved. There was no evidence of well-demarcated hemorrhage or contusion within the brain.

Eyes: Both eyes were present; however, the left globe was collapsed and the lenses were displaced ventrally in both eyes.

Peribullar region: There was an extensive soft tissue mass in the left medial peribullar space that had irregular, but well-defined margins and attenuation values consistent with peribullar parasites. The sinuses were well pneumatized. There was also minor clotting in the retrobullar spaces bilaterally.

Internal auditory canal (IAC)/Acousto-Vestibular/Facial Nerve: The internal auditory canals were well-defined with no evidence of blood or other abnormal material.

Middle ear: The middle ear cavities were normal with intact and normally configured ossicles and round windows. A small moderate density mass at the right window was consistent with a minor blood clot.

Inner ear: The canals were symmetrical and normal in appearance. There was no evidence in the available scans of abnormal intracochlear blood or other cochlear compromise.

Post-cranial features: Fatty tissues throughout the body were poorly preserved. Thoracic scans showed partial congestion and atelectasis of the right and to a much lesser extent, left lungs. There were few small, discrete, high density inclusions in both lungs consistent with calcified parasitic granulomas.

Gross and Histologic Diagnoses

- 1). Cerebrum, meninges: Congestion, multifocal, moderate.
- 2). Liver: Hepatitis, portal, mild, multifocal with biliary ductular hyperplasia and periductular fibrosis.
- 3). Ear, peribullar (Gross diagnosis): Hemorrhage, moderate, focally extensive with intralesional nematode parasites.
- 4). Lung: Bronchopneumonia, granulomatous and eosinophilic, multifocal, mild, with few adult and larval nematodes.
- 5). Skin, right mandible, dorsal to left eye, and labia (Gross diagnosis): Abrasions, moderate, multifocal.

6). Hypodermis, midmandible and melon: Contusions, multifocal, moderate (Gross diagnosis).

Comments and Conclusions

Postmortem scavenging, autolysis and freeze artifact hampered histological evaluation of examined tissues. Overt pathologies consistent with acoustic trauma were not apparent. The cause of death of this animal could not be determined. The body condition was good and based on the axial muscle mass, was considered within normal range (Table 3). The most significant necropsy findings included an organized clot around the spinal cord and basioccipital region, midmandibular and midmelon contusions, and dark red fluid beneath the cerebral meninges. Although extravasated fluid compatible with blood was noted grossly and in CT scans, there were no well-defined areas of hemorrhage in the intracranial spaces. Poor tissue quality precluded making any conclusions about pre or post mortem hemorrhage or extravasation. These changes are likely due to perimortem agonal thrashing; however, antemortem physical trauma cannot be ruled out.

Multisystemic parasitism is a common finding in wild porpoises and when mild, as in this case, it is not usually clinically significant. The pulmonary nematodes were most likely *Halocercus* spp and the hepatobiliary change was likely due to *Campula* spp.

Microbiology isolated light mixed growth of *Pseudomonas* spp, alpha *Streptococcus* spp, nonhemolytic *Escherichia coli* and heavy growth of *Clostridium perfringens* from the intestine, and either light mixed or solitary growth of *Pseudomonas* spp, nonhemolytic *E. coli* or *Acinetobacter johnsonii* from multiple internal viscera (Table 5). No *Salmonella* spp were isolated from the small intestine. Based on the lack of significant attendant inflammatory infiltrate and with the extent of autolytic change in examined tissues, these bacteria were considered post mortem invaders. Fecal floatation and sedimentation were negative for parasites. There was no detectable domoic acid within ingesta as determined by solid phase extraction (SPE) and analysis by high pressure liquid chromatography (HPLC). PCR of pooled lung, lymph node, spleen and brain was negative for Morbillivirus and consensus *Brucella* spp and follow up viral culture on Mabin Darby and Vero cell lines was negative. Trace mineral and vitamin A analysis of the liver and kidney were within normal reference limits (Table 6).

03NWR05003

History

This porpoise was reported stranded at County Park on Dungeness Spit (Figure 1) on 4 May 2003. A non-veterinary primary responder performed a cursory gross examination of the carcass and determined that this animal was pregnant with a fetus presumed to be in the third trimester. Only the head and fetus were collected and frozen. A CT scan was performed on the head, but it was not examined further during the necropsy session due to advanced decomposition. No photograph of this animal at time of stranding was available.

CT Findings

Only cranial images were produced for this animal. The head was decapitated at the occiput and was heavily flensed.

Cranial soft tissues: The majority of soft tissues were removed on the right and dorsal surfaces of the head, including all dermis, fats, and musculature. The remaining tissues were in poor post mortem condition. The left mandibular fats, like the brain, had extensive areas of fissures and granular, crystalline regions that were indicative of freeze-thaw artifact that compromised the tissues. The narial passages were filled with high contrast material and could not be assessed. The sinuses were partially occluded with poor pneumatization.

Intracranial/brain: The skull was intact except for the right parietal region which was disrupted. A bone fragment penetrated deep into the right parietal and temporal lobes of the brain and lodged adjacent to the right lateral ventricle. The lack of brain density changes in this area suggested post mortem trauma. The brain was intact and had a uniform granular appearance, consistent with extensive freezer artifact and the effects of freeze-thaw cycles. The brain was severely autolyzed.

Eyes: The right eye was missing and the left globe was collapsed.

Peribullar region: The spaces were essentially normal bilaterally for an animal in this severe state of decomposition.

Internal auditory canal/Acousto-vestibular/Facial nerve: The internal auditory canals were normal with partial degeneration of cranial nerves VIII and VII.

Middle ear: The ossicles were intact and normally configured bilaterally, and the round and oval windows were intact.

Inner ear: The canals were symmetric and normal.

The head was mostly denuded of soft tissues, and the remaining tissues exhibited signs of freeze-thaw artifact which compromised tissue quality. There were broad post mortem degenerative changes with poor preservation of most structures. Although there was no evidence in these scans of abnormal intracochlear blood or other cochlear compromise, the poor state of preservation made conclusions about the health of these ears impossible.

03NWR05005

History

This harbor porpoise was initially observed on 4 May 2003 wrapped in a fishing net (Figure 3) on Jackson Beach, San Juan Island (Figure 1). The carcass was collected on 5 May and stored in the UWFHL freezer, then transferred to the NMML- 32 freezer on 2 July 2003.



Figure 3 – Porpoise 03NWR05005 showing initial presentation of animal entangled in a fishing net (4 May 2003) (Photo: Whale Museum).

Gross Findings

An immature 126 cm total length, 33.5kg (does not represent true body mass due to extensive scavenger damage and post-mortem condition) female harbor porpoise was presented dead, 24 July 2003, in good body and fair post mortem condition (Figure 4). The right side of the carcass had extensive scavenger damage that extended deep to the blubber and on the left dorsolateral aspect of the mid caudal peduncle, there were small superficial scavenger bite marks.



Figure 4 – Right lateral photograph of porpoise 03NWR05005 at time of necropsy (24 July 2003). Due to lack of cutaneous net impressions, the entanglement was considered post mortem. The loss and fissuring of skin along the lateral aspect of the flank is attributed to post mortem decomposition and desiccation (Photo: B. Hanson).

Tubercles were present along the leading edge of the dorsal fin. The right eye was absent and the right mandibular fat pad avulsed by scavenging. Throughout the head and fascial region, there were extensive cutaneous abrasions; the left mandibular fat and underlying mandibular and rostral periosteum and bone were dark red. The periosteum was widely separated from the body of the mandible.

Nervous system: The inner aspect of the calvarium and cerebral surface were diffusely dark red (Figure 5). At the level of the occipital condyles, the dorsolateral aspects of the spinal cord were invested with a moderate amount of dark red gelatinous material. A few nematodes were present in the left peribullar space with accompanying hemorrhage. No parasites were apparent in the contralateral peribullar space.

Digestive system: Within the porta hepatis, a sparse number of subcapsular bile ducts were variably dilated by trematodes interspersed within small to moderate amounts of black mucoid deposits. Serial sections of the pancreas disclosed mild periductular fibrosis. A small number of nematodes were noted within the first compartment of the stomach. There was a moderate amount of chyme throughout the mesenteric lymphatics.

Respiratory system: The left lung was mottled dark red to pink and slightly depressed with few intervening light pink areas. Pink froth was present within the lumen of major bronchi.

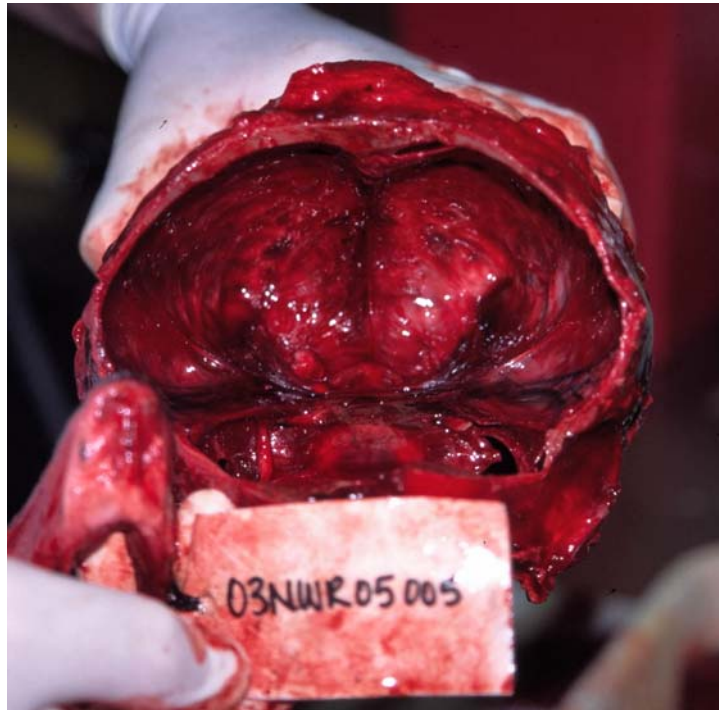

Figure 5 – Porpoise 03NWR05005 – The calvarium has been removed and the superficial aspect of the brain exposed. Note the diffuse red black discoloration of the superficial aspect of the brain. This change is associated with freeze artifact and post mortem decomposition (Photo: B. Hanson).

There were no apparent lesions within the cardiovascular, urogenital, hemolymphatic, musculoskeletal or endocrine systems.

CT Findings

This animal was not scanned.

Gross and Histologic Diagnoses

- 1). Cerebrum, meninges; mandibular fat pad; peri-spinal fat; larynx, fibroadipose tissue and periosteum: Congestion, multifocal, moderate.
- 2). Cerebrum: Meningoencephalitis, lymphocytic, multifocal, mild.
- 3). Liver: Cholangiohepatitis, granulomatous and eosinophilic, multifocal, moderate, with biliary ectasia, periductular fibrosis and many trematode eggs and adults.
- 4). Lung: Bronchopneumonia, granulomatous and eosinophilic, multifocal, mild, with many nematodes.
- 5). Peribullar space, left (Gross diagnosis): Hemorrhage, mild, focally extensive, with intralesional nematodes.

Comments and Conclusions

Autolysis, freeze artifact and post mortem scavenging impeded gross examination and microscopic assessment of multiple tissues. Although this animal was wrapped in a net on initial recovery, the lack of cutaneous (web) impressions suggests that this entanglement likely occurred post-, rather than antemortem. Based on Read and Murray (2000), animals caught in large-mesh multifilament net exhibit mutilated appendages; however, this animal did not exhibit any external signs of being caught in gear. The animal was robust and had no other evidence of trauma, which is consistent with, but not diagnostic of death in fishing gear. Therefore, the cause of death is uncertain. Cytology of the frozen lung airways failed to reveal any algae suggestive of agonal salt water aspiration. Based on a higher than normal blubber mass and despite slightly reduced axial muscle component this animal was graded in good body condition (Table 3). The extensive areas of cutaneous abrasion along the left side of the head were consistent with contact, movement along rough substrates, and scavenger attacks. Subjacent to the abraded areas, there was multifocally extensive congestion of left lateral jaw fats, consistent with an agonal or terminal process. The nares were clear with no sign of contusion or hemorrhage. The grossly noted discoloration of the brain and calverium was due to post mortem autolysis and freeze-thaw artifact within the superficial neuropil (Figure 5). There was no microscopic indication of acute hemorrhage in the examined brain sections. The mild meningoencephalitis was nonspecific and would not likely have been clinically significant. The multisystemic parasitism (retrobullar, hepatic, pulmonary and enteric) in this animal is commonly observed in wild harbor porpoises. The biliary parasites were most likely *Campula oblongata* and would not have contributed significantly to impaired liver function. The lungworm infection was low grade and likely due to *Halocercus* spp and the unilateral, peribullar nematodes were morphologically consistent with *Stenurus* spp. The gastric nematodes were most likely *Anisakis* spp. In published case reports of harbor porpoise parasitism, infection is commonly recognized (Raga *et al.*, 2002). Aerobic culture yielded light variable mixed growth of *Aeromonas hydrophila*, *Enterobacter* spp, *Pseudomonas* spp from multiple

internal viscera and heavy growth of *Clostridium perfringens* from the intestine (Table 5). No bacteria were isolated from the urine or kidney and fungal culture of the lung and lymph nodes was negative. Based on the extent of decomposition and lack of attendant inflammatory infiltrate in select tissues, these bacterial isolates were most likely post mortem invaders. With the exception of calcium values, trace mineral analysis of the liver and kidney proved within normal reference limits (Table 6). The increased liver calcium levels were likely due to dystrophic mineral deposition associated with the chronic cholangiohepatitis and the markedly reduced vitamin A values were presumably related to the extent of autolysis. Interpretation of the eye fluid analysis results was hindered due to the lack of available normal data in this species; based on extrapolation from terrestrial mammals, the calcium, magnesium, phosphorus and BUN appeared elevated and these increased values most likely represented post mortem change (bacterial overgrowth, putrefaction), blood contamination, or less likely, systemic homeostatic derangements associated with impaired renal function. The cause of death of this animal was not evident.

03NWR05006

History

This porpoise was found and collected at South Beach on San Juan Island (Figure 1) on 5 May 2003 and stored in the UWFHL freezer with subsequent transfer to the NMML-32 freezer on 2 July. No photograph of this animal at time of stranding was available.

Gross Findings

An adult 152 cm total length, 48.5 kg female harbor porpoise with moderate reproductive activity (corpora lutea in ovaries) was presented dead, 23 July 23, 2003, in moderate body (Table 4) and in very poor post mortem condition (Figure 6). The epidermis was missing throughout the ventrum and along the left flank. Extensive abrasions were present throughout the external surface of the head with gravel and debris filling the laryngeal cavity, esophagus and nares. The ventral fats and musculature of the head were degraded.

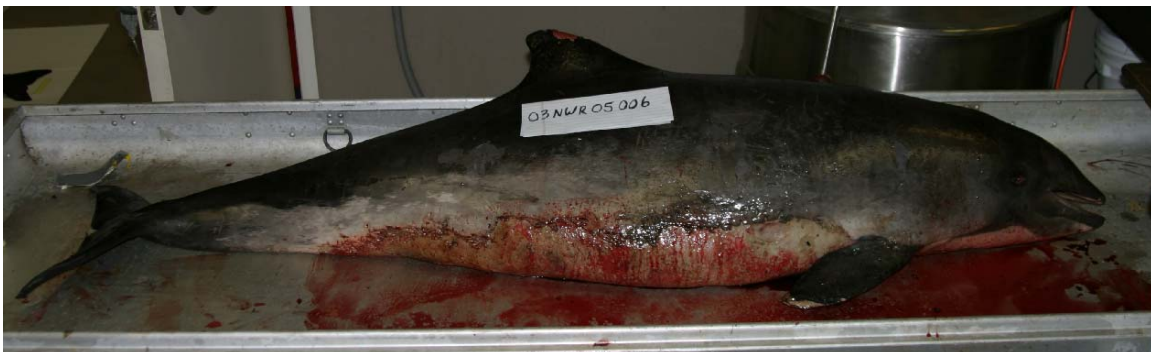

Figure 6 – Right lateral photograph of porpoise 03NWR05006 at time of necropsy (23 July 2003) (Photo: B. Hanson).

Nervous system: There was dark red fluid within the subdural space, and the basioccipital bone was dark red. Within the right retrobullar and peribullar spaces, there

was a moderate amount of dark red fluid. There was a moderate amount of congestion of the cerebrum with red discoloration of the surface and subdural pooling of dark red fluid.

Respiratory System: The lungs were homogeneously dark red (congestion), with a few scattered 1 mm hard white foci throughout the parenchyma. There was a small amount of red foam within the airways.

Cardiovascular System: There was a moderate amount of fat surrounding the coronary arteries.

Digestive System: There was a moderate amount of sand throughout the oral cavity. The pancreas and intestines are autolyzed. The liver had two firm, 2-3 cm, well delineated black to red areas on the capsule. Bile ducts in the underlying parenchyma were ectatic with thick walls. There were a few trematodes within the lumen. Within the nonglandular compartment of the stomach there was a 3 x 2 x 1 cm raised area with a few crateriform ulcers containing 30-40 attached nematode parasites (*Anisakis* spp) while the forestomach contained 2,000-3,000 free-floating nematodes.

Significant lesions were not apparent in the urogenital, endocrine, musculoskeletal and hemolymphatic systems.

CT Findings

Cranial, thoracic and abdominal images were analyzed.

Cranial soft tissues: A majority of tissue suites were intact, but in relatively poor condition. The right mandibular fats were well-defined, and the left lateral fats subjacent to the abraded skin had mid-low density regions suggestive of either congestion or extravasated blood.

Intracranial/brain: The skull appeared normal. The brain was intact, but subregions were poorly defined, suggesting moderate to severe autolysis. There were extensive areas of extravasated fluid with a HU density compatible with blood in the subarachnoid and subdural regions. As the meningeal divisions were poorly defined, determination of the precise fluid distribution was not possible.

Eyes: Both eyes were present; however, the left globe was collapsed and the lens was absent. In the right eye, the lens was displaced ventrally.

Right ear: There was an extensive soft tissue mass in the right dorsal peribullar space that was consistent with an organized clot. The internal auditory canal was well-defined with no evidence of blood or other abnormal material. Cranial nerves VIII and VII were normal. The middle ear cavity, ossicles and round window were normal (Figure 7). There was a minor blood deposit at the right round window.

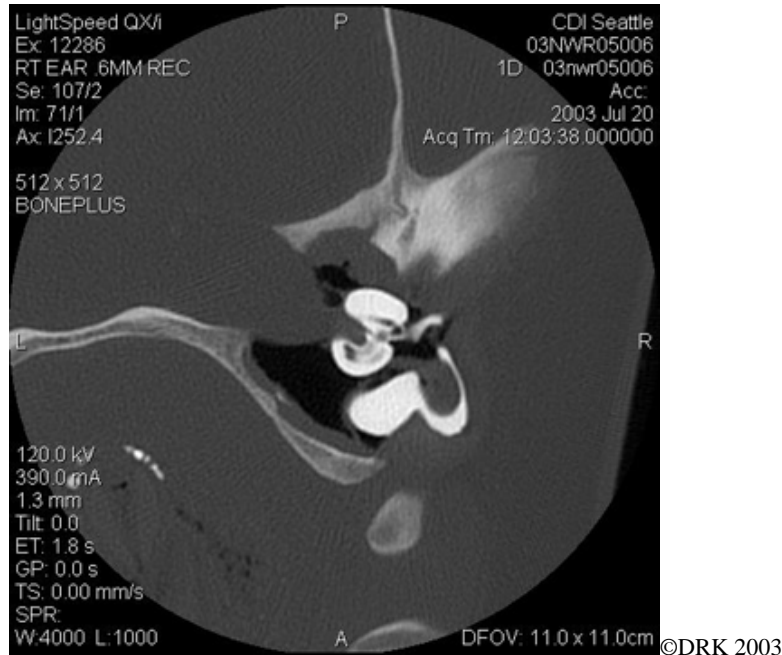


Figure 7 – CT scan image at level of ossicles of right rear (03NWR05006) (Image: D.R. Ketten).

Left ear: The peri and retrobullar spaces were normal. The left tympanic bone was possibly partially demineralized. The internal auditory canal was normal as were cranial nerves VIII and VII. The middle ear cavity, ossicles, and round and oval windows were normal.

Post-cranial features: There were extensive abrasions across most of the body. Thoracic scans showed both lungs were collapsed and congested, with the right lateral lung more compromised than the left. There were substantial numbers (50-100) of small, high density parasitic nodules which were most evident in the anterior lobes of both lungs.

Gross and Histologic Diagnoses

- 1). Colon: Colitis, subacute, multifocal, transmural, moderate, with peritonitis.
- 2). Lymph node: Lymphadenitis, subacute, multifocal, moderate, with lymphoid hyperplasia.
- 3). Lung: Bronchopneumonia, granulomatous and eosinophilic, multifocal, moderate, with many adult nematodes and larvae.
- 4). Forestomach: Gastritis, proliferative and ulcerative, lymphocytic and eosinophilic, focally extensive, moderate, with few adult nematodes.
- 5). Liver: Cholangiohepatitis, granulomatous and eosinophilic, multifocal, mild, with biliary ectasia, periductular fibrosis and many trematodes.
- 6). Ear, peribullar (Gross diagnosis): Hemorrhage, moderate, focally extensive with intralesional nematode parasites.

Comments and Conclusions

Although post mortem change hindered microscopic assessment of multiple tissues and precluded evaluation of select segments of bowel, death was likely attributed to

salmonella septicemia. *Salmonella Newport* Group C2 was cultured from the lung, hilar lymph node, kidney, spleen, liver, thymus, mesenteric lymph node and small intestine (Table 5). The pulmonary alterations observed in the right lung on thoracic CT scans were compatible with the gross and histological findings of bronchopneumonia. A review of the literature disclosed a small number of previous case reports of *Salmonella enterica* (antigenic formula 4,12:a:-) in harbor porpoises (*Phocoena phocoena*) in Scotland (Foster *et al*, 1999); however, salmonellosis is more commonly identified in sea otters, harbor seals and captive walruses (Calle *et al*, 1995; Thornton *et al*, 1998). In an overview of marine mammal disease surveillance findings in Los Angeles (Schroeder *et al*, 1973), there was a single case report of *Salmonella Newport* in a California sea lion and in a subsequent publication, this serotype was identified in one of four and two of 18 (the latter consisting of both *Newport* and *Montevideo*) California sea lions at a rehabilitation facility in 2002 (Smith *et al*, 2002). These bacteria are highly adapted to a number of human and animal hosts that may present with a wide variety of lesions, such as a gastroenteritis or generalized septicemia. The precise source of the bacteria in this case is unknown. Some serotypes of *Salmonella* are capable of survival and propagation in salinity as high as 3.5%. Based on the transmural inflammatory infiltrate within segments of intestine, infection was most likely *per os* with subsequent intestinal colonization, proliferation and invasion. PCR of pooled lung, lymph node, spleen and brain was negative for Morbillivirus and consensus *Brucella* spp and follow up viral culture on Mabin Darby and Vero cell lines was negative. Chemical analysis of the intestinal contents was negative for domoic acid. Histopathology confirmed the grossly noted pulmonary, hepatic and gastrointestinal parasitism and revealed an intermediate grade enteritis, lymphadenitis and peritonitis. Fecal floatation and sedimentation disclosed a moderate number of gastrointestinal nematodes and sedimentation was unremarkable for trematode parasites. This intensity of parasitism is commonly identified in porpoises. Due to the extent of post mortem decomposition and scavenging, an accurate assessment of the body condition could not be made (Table 3). Trace mineral and vitamin A analysis of the liver and kidney were within normal in house reference limits (Table 6). No overt lesions consistent with acoustic trauma were noted on the CT scans. Although there were no well-defined regions of hemorrhage in the intracranial spaces, the poor tissue quality precluded precise determination of deposition. The ears were poorly preserved, but essentially normal bilaterally.

03NWR05007

History

This porpoise was initially observed and collected at Dungeness Spit (Figure 1) on 6 May 2003, stored in the USFWS/Dungeness National Wildlife Refuge freezer and then transported to the NMML-32 freezer on 2 July 2003. No photograph of this animal at time of stranding was available.



Figure 8 – Left lateral photograph of porpoise 03NWR05007 at time of necropsy (22 July 2003) (Photo: J. Gaydos).

Gross Findings

A 145.5 cm total length, 38.5 kg, immature female harbor porpoise was presented 22 July 2003 in good physical condition. Initial carcass condition was coded as 4+, but the internal exam revealed that the deep tissues were in moderate post mortem condition (Figure 8). There were ample subcutaneous and abdominal adipose stores and the animal was well muscled (Table 3). Extending from the mid thoracic region to insertion of the peduncle, along the left ventrolateral aspect of the torso there was multifocally extensive post mortem scavenging. Along the left lateral aspect of the mid thoracic region, there were three small, well-circumscribed circular scars. Throughout the right flank, there was variably extensive subcutaneous congestion and dependant stasis. Along the dorsolateral aspects of the peduncle, there were multiple 0.6-0.8 cm diameter superficial aggregates of diatoms. On incision of the subcutaneous tissue adjacent to both mammary glands, approximately 2 ml of tan orange, glistening viscous material exuded and within the lumen of the main mammary ducts, there was a solitary 3-4 cm long nematode parasite. Within the perineum, a small number of nematodes were widely dispersed throughout the subcutis.

Respiratory system: The right and to a much lesser extent left lung lobes were mottled light pink with variably sized intervening, mildly depressed dark red areas. There was moderate visceral pleural fat accumulation. A small amount of stable pink froth was present within the bronchi.

Digestive system: Within the hilar region of the liver, there were moderate accumulations of trematode parasites. The glandular compartment of the stomach was contracted and empty. Along varying levels of the pancreas, between 5-35% of the ductules were circumscribed by thin to moderately thick margins of fibrous connective tissue.

There were no apparent lesions within the cardiovascular, urogenital, nervous, musculoskeletal, or hemolymphatic systems.

CT Findings

Cranial, thoracic and abdominal images were analyzed.

Cranial soft tissues: All the tissues were in moderate to poor condition. The nares and oral cavity were filled with high density material attributed to sediment and sand. Both sinuses were partially opacified with the right more compromised than the left and containing some relatively high density material.

Intracranial/brain: The skull, cerebellum and midbrain were normal in appearance. In the subtemporal region of the brain, there were mid to low density accumulations that were consistent with pooled extravasated blood (Figure 9).

Eyes: The left globe was enucleated, but the right was present.

Peribullar region: The regions were clear and well aerated bilaterally with well-defined ligaments.

Internal auditory canal/Acoustic-vestibular/Facial Nerve: No indication of blood or other abnormal material was present. Cranial nerves VIII and VII nerves were intact but degenerated.

Middle ear: The cavities, ossicles and round windows were normal bilaterally.

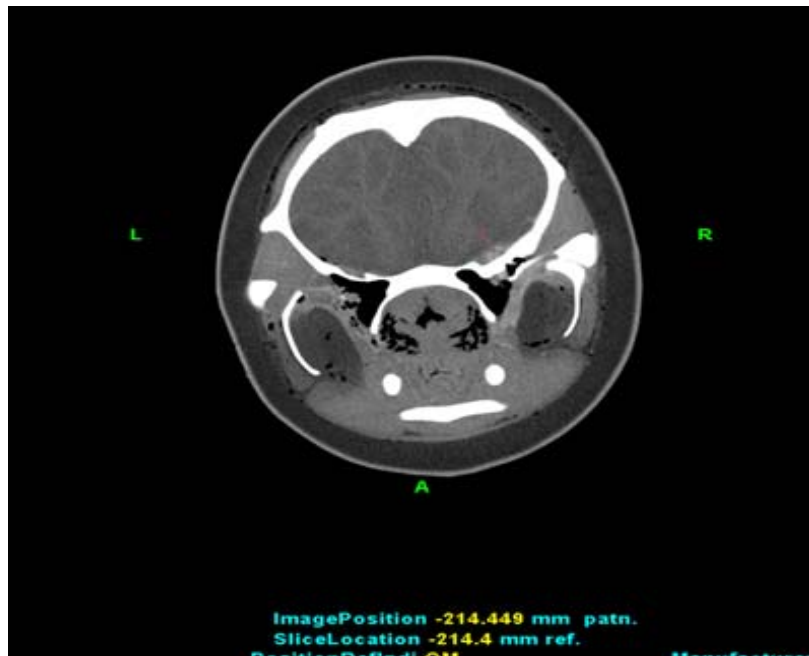


Figure 9 – CT scan image demonstrating mid to low density structures in the subtemporal region (03NWR05007) (Image: D.R. Ketten).

Inner ear: The canal structures were symmetrical and normal in appearance. In both ears, there were minor mid attenuation deposits consistent with intracochlear blood.

Post-cranial features: Thoracic scans showed that the cranioventral lung lobes were congested and collapsed bilaterally, with the right more extensively affected than the left.

Both lungs had multiple high density nodules or calcified cysts consistent with parasitic pneumonia.

Gross and Histologic Diagnoses

- 1). Cerebrum, meninges and larynx: Congestion, diffuse, moderate.
- 2). Heart: Myocarditis, granulomatous and eosinophilic, multifocal, mild.
- 3). Liver: Cholangiohepatitis, granulomatous and eosinophilic, multifocal, moderate, with biliary ectasia, periductular fibrosis and many trematode eggs.
- 4). Lung: Bronchopneumonia, granulomatous and eosinophilic, multifocal, mild, with nematode adults and larvae.
- 5). Mammary gland: Mastitis, lymphocytic and eosinophilic, chronic, multifocal, mild.
- 8). Pancreas: Fibrosis, periductular, mild, multifocal, chronic.
- 9). Skin, right flank: Dermatitis, mild, multifocal, chronic (resolving scars) (Gross diagnosis) with hypodermal nematode parasites.
- 10). Skin, left ventrolateral thorax: Laceration, mild, focal, subacute (Gross diagnosis)
- 11). Ear, intracochlear: Presumptive hemorrhage, mild, multifocal.

Comments and Conclusions

There were no overt lesions within the examined tissues that would account for the death or stranding of this animal. Close evaluation of the oropharyngeal, peribullar and periorbital spaces failed to reveal any lesions consistent with an acoustic related trauma, and microscopic assessment of the larynx disclosed only low-grade mucosal erosion and congestion. Gross examination disclosed multifocal areas of pulmonary congestion which may have accounted for the CT findings. The cause of the myocarditis is not evident. Parasitism is a consideration due to the eosinophilic inflammation. However, it is mild and likely clinically insignificant. The ears were normal bilaterally by CT scan with some increased density in the cochlear canal consistent with intracochlear blood. Gross examination of the nares did not reveal any luminal deposits and the composition of the high density foreign material detected by CT scan is unknown. The scars noted along the right lateral aspect of the cranial thoracic cavity likely represented a long past traumatic or infectious process and appeared restricted to the superficial dermis. Cytology of the punctate, orange mucoid cutaneous deposits revealed numerous diatoms. Epidermal diatoms have previously been reported in Dall's porpoises (*Phocoenoides dalli*) in the Northern Pacific Ocean and are considered incidental findings (Holmes *et al.*, 1993). Trace mineral and vitamin A analysis of the liver and kidney proved largely within normal reference limits (Table 6); increased liver calcium is likely related to post mortem mineral deposition or chronic inflammatory associated with the liver flukes. Examination of the aqueous humor disclosed significantly increased phosphorus and blood urea nitrogen relative to terrestrial animal values. Efforts are ongoing to determine normal reference values for small cetaceans and based on the lack of associated change within the examined tissue and degree of post mortem change, interpretation of these data is hindered; abnormalities with phosphorus levels may be associated with lactation or some other disease processes. Cytologic evaluation and bacterial culture of the grossly noted mammary gland discharge revealed abundant vacuolated and proteinaceous background with scattered exfoliated cuboidal and squamous epithelia, histiocytes, lymphocytes and fewer neutrophils with small numbers of extracellular cocci and bacilli.

Histopathology disclosed a low grade, chronic inflammatory process presumably due to intra- and periductular nematode parasites. These parasites were morphologically consistent with *Crassicauda* spp; although the intensity of infection may have interfered with normal lactation, this burden is not considered pathologically significant. The bile duct parasites were most likely *Campulla* spp and the lungworms were presumably *Halocercus* spp. Multisystemic parasitism is commonly identified within wild stranded harbor porpoises and in this animal, cumulatively would not have contributed significantly to antemortem morbidity. Fecal floatation and sedimentation were negative for parasites. Aerobic culture of the milk isolated light growth of nonhemolytic *Streptococcus* spp and light mixed growth of *Pseudomonas fluorescens* and *Enterobacter* spp from the lung (Table 5). Based on the extent of post mortem change and lack of significant inflammatory infiltrate, these bacteria were likely post mortem contaminants. Aerobic culture of multiple internal viscera, including brain, mammary gland, spleen, spinal cord, rectal swab, thymus and thoracic fluid, yielded light growth of *Enterobacter* spp with no bacteria isolated from the kidney, urine, or liver (Table 5). Special culture for fungi and *Salmonella* spp were negative. In two of six sections of pancreas, the fibrotic scores were 5 and 35 percent. Analysis of intestinal contents for domoic acid was negative.

03NWR05008

History

This animal was first reported stranded on 6 May 2003 on Discovery Trail at Ennis Creek (Figure 1). The head was removed, collected for examination and delivered to the NMML-32 freezer on 9 May 2003 (Figures 10 and 11). The remainder of the carcass re-floated and was later retrieved on 16 May.

Gross Findings

The head of this adult male was presented on 22 July 2003 in poor post mortem condition (Figure 12). Throughout the head, there was extensive deterioration of blubber and fat pads. The melon was clear. Within the superficial mandibular fat pads, there was variable congestion and the deep pads were clear. Multifocal blubber degeneration and autolysis was noted subjacent to bird scavenging. A moderate number of (7-10) teeth were missing from the right mandible. The right eye was ruptured and collapsed (scavenged) and the left eye was autolytic. The remainder of the porpoise, 146 cm truncated length, approximately 40 kg and with minimal reproductive activity, was presented 24 July 2003, in fair to moderate physical condition and poor post mortem state (Figure 13). The animal was fairly fleshed. Along the left lateral aspect of the mid thoracic and cranial abdominal region, there was focally extensive loss of the skin, blubber and scapula with maceration of the subjacent intercostal muscles. Within the inguinal region, there were a moderate number of subcutaneous and hypodermal calcified parasites.

Digestive system: Throughout the abdominal cavity, involving numerous loops of small intestine as well as the peritoneum and serosal surface of multiple viscera, there were



Figure 10 – Left lateral photograph of head of porpoise 03NWR05008 three days (9 May 2003) after initially reported stranded (Photo: Olympic Coast National Marine Sanctuary).



Figure 11 – Head-on photograph of left lateral side of porpoise 03NWR05008 three days (9 May 2003) after stranding was initially reported, demonstrating the extent of scavenger damage (Photo: Olympic Coast National Marine Sanctuary).



Figure 12 – Left lateral photograph of head of porpoise 03NWR05008 at time of necropsy (22 July 2003) (Photo: D. Ketten).



Figure 13 – The remainder of porpoise 03NWR05008 at time of necropsy (24 July 2003) (Photo: B. Hanson).

multifocally extensive adhesions which were readily reduced by digital manipulation; on exposed surface, the serosa was finely granular.

There was moderate enlargement of the mesenteric lymph nodes. Multifocally within the liver, bile ducts were dilated with thickened walls and contained trematodes.

Urogenital system: The kidneys were detached from the peritoneal surface and free within the dorsal peritoneal cavity. Within the right epididymis, immediately dorsal to the testes, there was a 2 cm diameter, firm, nodule with multiple adhesions to the surface of the testes; on incision, there were abundant amounts of pale yellow white mucoid material bound by a moderately thick capsule.

Respiratory system: Bilaterally, the lungs were collapsed and the dorsal visceral pleura overlaid by abundant amounts of small pebbles and stones. On incision of the trachea and extending throughout the virtually the entire length of the caudal bronchi, the lumen contained a moderate amount of small stones. Within the lumen of the nasopharynx and nares, there were a moderate number of nematode parasites.

Nervous system: At the level of cervical vertebrae 1 and 2 segmentally overlying the left ventral aspect of the spinal cord, there was a small amount of dark red gelatinous material. Interspersed within a small amount of blood, within the left peribullar region, there were moderate accumulations of nematodes. Smaller numbers of nematodes were noted in the right retrobullar area.

There were no apparent lesions within the musculoskeletal, hemolymphatic, cardiovascular, or endocrine systems.

CT Findings

Only cranial scans were conducted. The head was decapitated at the level of the occiput. Readings suggestive of degenerated tissues were observed as well as large deposits of high density material in the airways and esophagus, attributed to sand and sediment.

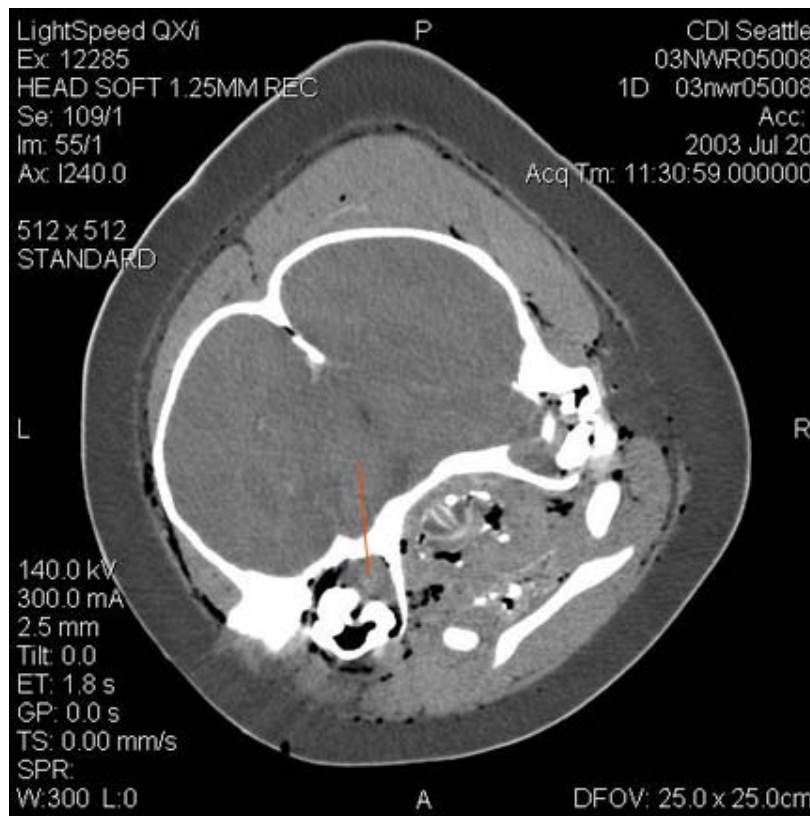


Figure 14 – CT scan image of 03NWR05008 at level of the tympano-periotic bone illustrating a tissue mass medial to the left tympano-periotic bone (orange arrow just below center of image) (Image: D.R. Ketten).

Cranial soft tissues: High density, mixed material occluded the lumen of the left and to a much lesser extent the right nares, particularly the left sac.

Intracranial/brain: The skull features were normal. The brain was relatively uniform in appearance, suggestive of poor preservation.

Eyes: The left eye was intact, and the right eye was present and the lens was displaced ventrally.

Peribullar region: The sinuses were generally clear bilaterally. A substantial, well-defined mass of tissue was present medial to the left tympano-periotic bone with a similar, but smaller mass, on the right which were both consistent with bundled parasites (Figure 14).

Internal auditory canal/Acousto-vestibular/Facial nerve: The IAC, retrobullar areas, and cranial nerves VIII and VII were normal bilaterally.

Middle ear: The cavities, ossicles, as well as round and oval windows were normal bilaterally.

Inner ear: The canals and intracochlear fluids were normal in both ears.

Gross and Histologic Diagnoses

- 1). Intestine; liver and kidney: Serositis and capsulitis, fibrinous, multifocal, mild, with many bacilli and few cocci.
- 2). Epididymis: Abscess, focal, moderate, chronic, with nematode eggs.
- 3). Liver: Cholangiohepatitis, granulomatous and eosinophilic, multifocal, moderate, with biliary ectasia, periductular fibrosis and many trematodes.
- 4). Lung: Bronchopneumonia, eosinophilic and granulomatous, multifocal, moderate, with nematodes.
- 5). Blubber, inguinal region: Steatitis, moderate, multifocal, granulomatous, chronic with intralesional parasites (Gross diagnosis).
- 6). Peribullar space: Hemorrhage, mild, focally extensive, with abundant intralesional nematodes (Gross diagnosis).

Comments and Conclusions

Profound post mortem decomposition impeded microscopic assessment of multiple tissues and precluded gross and microscopic assessment of the larynx and adjoining oropharyngeal tissue. The widespread serositis and peritonitis likely contributed to death of this animal. Lesions indicative of acoustic related injury were not evident. The CT analysis of this animal's brain, melon, skull, and ears was considered within normal limits for an animal of this code. Adequate nutritional assessment of this animal was hindered due to the extent of post mortem decomposition and scavenging (Table 3). Aerobic bacterial culture isolated light variable mixed growth of alpha *Streptococcus* spp, nonhemolytic *Escherichia coli*, *Enterobacter* spp and less frequently *Aeromonas hydrophila* from multiple internal viscera, including the epididymis (Table 5). Based on

the extent of putrefactive change, it was difficult to resolve the precise contribution of any of these bacteria to the grossly noted peritonitis. The possibility of post mortem bacterial overgrowth and loss of a more fastidious pathogen could not be discounted. Histopathology of the epididymal abscess revealed numerous larvated nematode ova interspersed within abundant amounts of mineral deposition that was peripherally circumscribed by dense bands of fibrous connective tissue. The ova were suggestive of *Crassicauda* spp and were considered an incidental finding. No significant pathogens were isolated by routine culture of the epididymis and the abscess was negative for *Brucella* spp by polymerase chain reaction. The hepatobiliary (*Campula* spp), peribullar (*Stenurus* spp), pulmonary (*Halocercus* spp), gastric (*Anisakis* spp) and subcutaneous (*Crassicauda* spp) parasitism are commonly observed in wild porpoises; no parasites were identified by fecal floatation or sedimentation. No fungi were isolated from lung tissue. Trace mineral and vitamin A analysis of the liver and kidney proved within normal reference limits (Table 6). The small amount of clotted blood surrounding the cervical spinal cord was likely associated with agonal struggling. The avulsed left eye and cutaneous defects within the fascial region were attributed to post mortem scavenging.

03NWR05010

History

This porpoise was initially reported stranded on 13 May 2003 at Admiralty Head on Whidbey Island (Figure 1). At the time, the carcass was fresh with little superficial damage, but blood was found in both eyes, the nares and oral cavity (Figure 15). On the morning of 14 May, a portion of the head and right side of the body were scavenged (Figure 16). The carcass was wrapped in plastic and transferred to NMML-32 that evening.

Gross Findings

An adult, 154 cm total length, approximately 55 kg, harbor porpoise was presented dead, 24 July 2003 in fair body condition. Initial carcass condition was coded as a 3+, but the internal exam revealed that the deep tissues were in a more advanced state of decomposition (code 4) (Figure 17). Throughout the ventrum, there was widespread bird damage. From the ventral aspect of the left mandible to the mid thoracic region, there is focally extensive loss of skin and blubber with exposure of the ribs and intracostal musculature (post mortem predation). Along the leading edges of the fluke and flippers, there was extensive loss of epidermis. There was a 10x12 cm dark red, edematous area on the left abdominal wall that extended from the blubber moderately deep into the underlying muscle. Both mandibular fat pads were stained red, the left darker than the right. Both peribullar sinuses contained hundreds of nematodes.

Nervous system: The left occipital crest was fractured. Along the fractured margins, the dura was dark red and separated from the underlying bone by dark red fluid. The internal surface of the calvarium and superficial aspect of the brain were diffusely dark red and the meninges were overlaid by a small amount of dark red fluid.

Respiratory system: The lungs were diffusely dark red and congested with rare 1 mm calcified white nodules. There was a small amount of dark red fluid in the airway.

Digestive system: Within the liver hilus, there were a few firm 1-2 cm diameter irregular subcapsular bile ducts that were moderately dilated by trematode parasites and black green tenacious material.



Figure 15 – Right dorsolateral photograph of initial stranding of porpoise 03NWR05010 on 13 May 2003 (Photo: S. Dubpernell).



Figure 16 – Right lateral photograph of 03NWR05010 the morning of 14 May 2003, showing extensive scavenger damage to head and thorax (Photo: S. Dubpernell).



Figure 17 – Right lateral photograph of 03NWR05010 at time of necropsy (24 July 2003) (Photo: B. Hanson).

Bile ducts within this area had thickened walls. The pancreas was autolyzed and there was no indication of periductular or interstitial fibrosis.

There were no apparent lesions within the urogenital, endocrine, hemolymphatic or cardiovascular systems.

CT Findings

This animal was not scanned.

Gross and Histologic Diagnoses

- 1). Bone, left occipital crest: Fracture, focally extensive, with hemorrhage (Gross diagnosis).
- 2). Adipose tissue, left mandibular fat pad; panniculus and skeletal muscle, left abdomen: Congestion, multifocal, moderate.
- 3). Adipose tissue: Atrophy, diffuse, mild.
- 4). Liver: Cholangiohepatitis, granulomatous and eosinophilic, multifocal, moderate, with biliary ectasia, periductular fibrosis and trematodes.
- 5). Lung: Bronchopneumonia, granulomatous and eosinophilic, multifocal, mild, with nematodes.
- 6). Ears, peribullar: Hemorrhage, moderate, focally extensive, with nematode parasites.

Comments and Conclusions

The most significant gross observation was the fractured left occipital crest with hemorrhage in the underlying tissues and left mandibular fat pad. Due to the lack of microscopic hemorrhage or inflammatory infiltrate, it was difficult to resolve whether this fracture was a post mortem event or incurred shortly before death, as there was insufficient time for a histological reaction to develop. The immediate cause of death is not evident; however, if this was a perimortem event, the trauma resulting in this fracture would have been sufficiently severe to account for the death of this animal. No overt lesions consistent with acoustic trauma were noted. The left abdominal subcutaneous hematoma was likely associated with blunt trauma. An adequate assessment of the nutritional status of this animal was not possible due to extent of post mortem decomposition (Table 3). The microscopically detected fat atrophy was indicative of a

negative energy balance. The peribullar parasites were morphologically consistent with *Stenurus* spp and the heavy burden would have presumably contributed to antemortem morbidity. In contrast, the parasitic pneumonia (most likely *Halocercus* spp) and cholangiohepatitis (presumably *Campula* spp) are considered low grade and incidental. The parasitic load from these latter two species is commonly observed in wild porpoises and presumably would not have contributed to antemortem morbidity. Fecal floatation and sedimentation were negative for parasites. There was no detectable domoic acid within ingesta as determined by SPE and analysis by HPLC. PCR of pooled lung, lymph node, spleen and brain was negative for Morbillivirus and consensus *Brucella* spp. Viral culture on Mabin Darby and Vero cell lines were negative. The pancreas was too autolyzed to score the extent of fibrosis. Trace mineral and vitamin A analysis of the liver and kidney were within normal reference limits (Table 6). Aerobic bacterial culture of the kidney, liver, mesenteric lymph node yielded light, mixed growth of *Enterococcus* spp, nonhemolytic *Escherichia coli*, and *Aeromonas hydrophila* (Table 5). There was moderate mixed growth of these bacteria in the spleen, lung and brain and heavy growth of *Enterococcus* spp and *Clostridium perfringens* from the small intestine. Based on the extent of autolysis and lack of attendant inflammatory infiltrate, these isolates are most likely due to post mortem overgrowth. There were no fungal pathogens isolated from the lung and special culture for *Salmonella* spp in the intestine was negative. Trace mineral analysis of the eye fluid (vitreous humor) revealed calcium levels of 7.7 mg/dl, magnesium of 20.79 mg/dl, a phosphorus of 64 mg/dl and a blood urea nitrogen of 57 mg/dl (Table 6). Although the BUN may appear elevated, the lack of established normal levels for healthy animals confounds interpretation of this data.

03NWR05011

History

The porpoise was first reported stranded at the high tide line on 16 May 2003 at Ediz Hook in Port Angeles (Figure 1), with blood coming from the eyes, nares, and oral cavity (Figure 18).

Gross Findings

An adult 136.5 cm total length, 37 kg female harbor porpoise was presented dead 23 July 2003, in good nutritional and fair post mortem condition with extensive scavenger damage (Figure 19). Throughout the left dorsolateral aspect of the head there was extensive subcutaneous hemorrhage. There were bilateral fractures and disarticulations of the zygomatic arches, parallel transverse and comminuted fractures of the left mandible, and multiple rostral skull base, including frontal bone and prefrontal fractures frequently admixed with substantial amounts of acute hemorrhage or overlaid by variably sized blood clots (Figure 20). Intercalated between the oral mucosa and palatine lobes and occluding the pterygoid sinus there was marked hemorrhage. Frank hemorrhage was within the lumen of the trachea, bronchi, deep within the nares, esophagus and oropharynx. The vasculature appeared prominent in the blubber and nuchal fat. There were focal abrasions on the rostral mandible and maxilla and small healed cutaneous lacerations along the leading edge of the dorsal fin, left fluke lobe and mid dorsal region of the caudal peduncle.



Figure 18 – Left ventral view of porpoise 03NWR05011 at time of initial discovery (16 May 2003) (Photo: Olympic Coast National Marine Sanctuary).



Figure 19 – Ventral photograph of 03NWR05011 at time of necropsy (23 July 2003) (Photo: B. Hanson).

Nervous system: Adjacent to the cranial fractures, there was extensive epi and subdural hemorrhage and the entire surface of the brain was dark red. In the left ear, there were numerous peribullar nematodes.

Cardiovascular and endocrine systems: Tissue surrounding the thyroid gland and thymus was dark red and moderately edematous. There was approximately 7 ml of dark red fluid within the pericardial sac.

Respiratory System: There was a moderate amount of dark red fluid within the trachea. The lungs were uniformly dark red, with rare 1mm white calcified parasitic nodules and there was approximately 75 ml of dark red fluid within the thoracic cavity.

Digestive System: The pancreas was light red to pink and a minimal amount of fibrosis surrounded the pancreatic duct. Diffusely, there was a moderate amount of chyme within

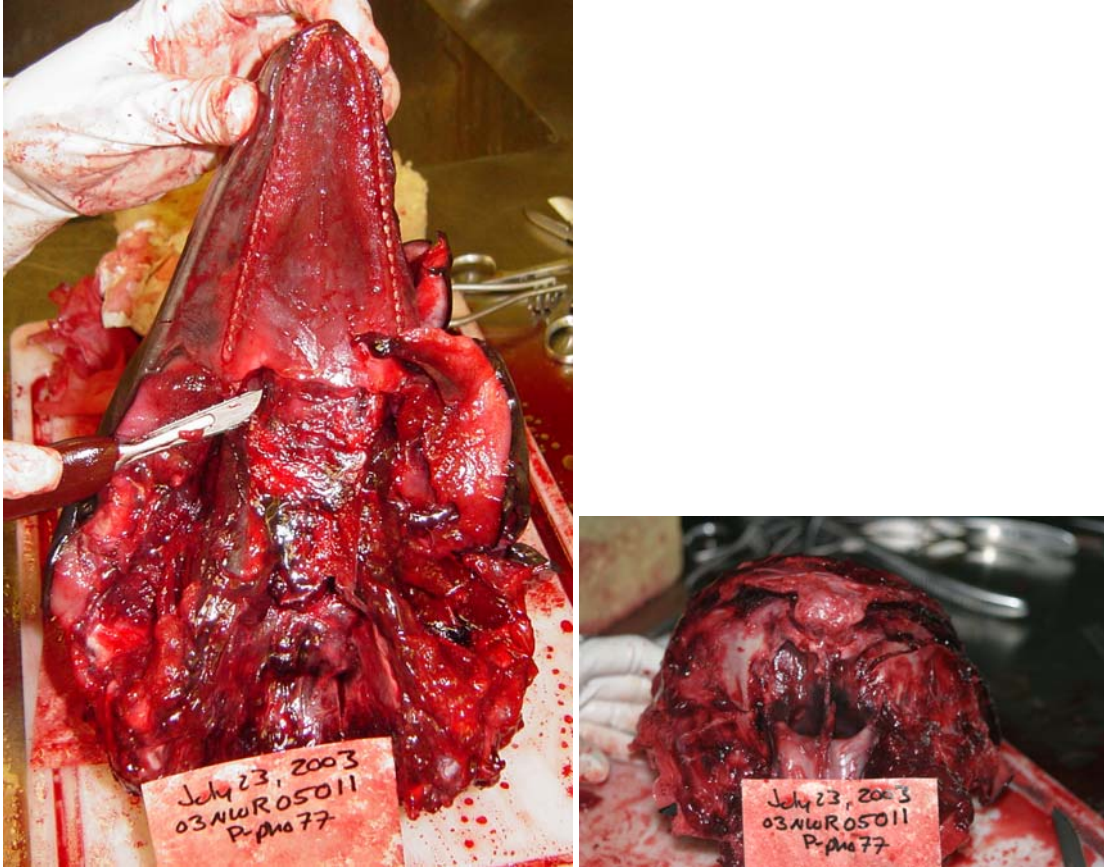


Figure 20 – Photographs of the ventral (left) and caudal (right) aspects of the skull of 03NWR05011 demonstrating multiple fractures (Photos: D. Ketten – left; B. Hanson – right).

the mesenteric lymphatics. There was a small amount of dark green to brown ingesta throughout the intestines.

There were no apparent lesions within the urogenital or hemolymphatic systems.

CT Findings

Cranial, thoracic and abdominal images were analyzed. The animal was in generally poor condition, and had extensive trauma evident particularly on the surface and within the head.

Cranial soft tissues: There were multiple areas of abrasions with the most compromised areas rostral. Sand or similar material was present throughout the mucosal and cutaneous surfaces of the head, particularly in the left dorsal nasal sac. There were extensive areas of contusion consistent with cranial trauma.

Intracranial/brain: The entire skull was severely compromised by multiple fractures, including longitudinal and comminuted fractures of the skull base, right occipital, left temporal, left parietal, left squamosal, frontal and left mandibular bones, with multiple skull fragments displaced (Figures 21 and 22). The left mandible had two longitudinal

fractures, three parallel fractures and one laterally displaced chip. The brain was homogenous, suggesting it was severely compromised as a result of the trauma inflicted on the skull.

Eyes: Both were present but collapsed.

Right ear: The peribullar areas and middle ears were normal. Bilaterally, the inner ears contained blood in the apical and middle turns.

Left ear: Blood was found in the apical and middle turns of the inner ear. The peribullar space contained two tissue masses: one an organized clot and the other a mass medial to the left tympano-periotic bone, with a similar mass within the middle ear cavity.

Multiple, small, dense spheroids within these soft tissue masses were most likely calcified parasitic bodies. There was also a tympanic bone fracture in the left lateral wall.

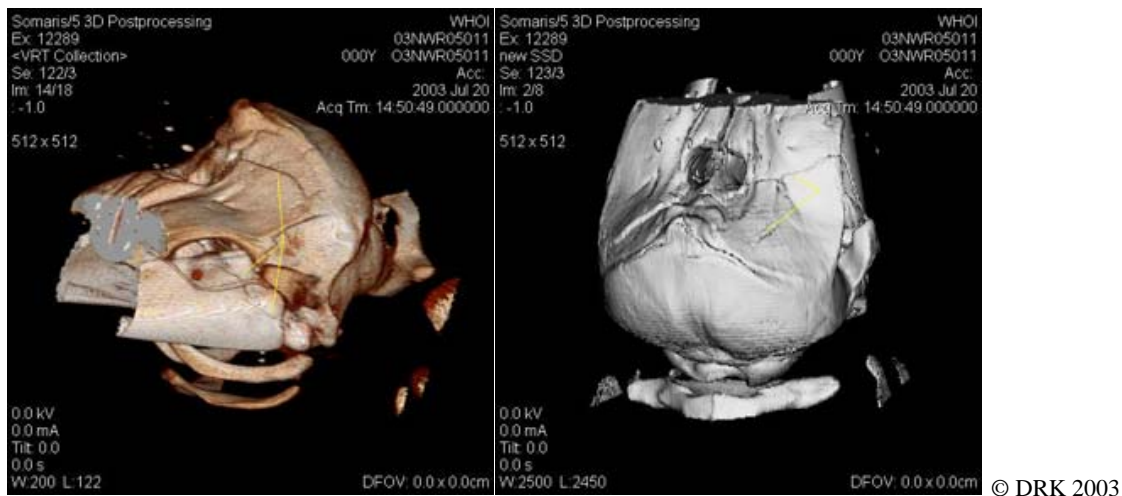

Figure 21 – A lateral 3D view (left) of 03NWR05011 showing the mandibular and frontal fractures (yellow arrows). The dorsal 3D view (right) shows a right frontal and maxillary fracture (yellow arrows) (Illustrations: D.R. Ketten).

Post-cranial features: The internal organs were partially autolyzed with some evidence of freeze-thaw artifacts within the liver. The lungs were congested and atelectatic with the right slightly more affected than the left. An ice block was evident in the right bronchus (Figure 23). Several dense foci within the trachea were attributed to sand or parasitic inclusions.

Cause of death: Given that the evidence from the histology shows the fractures were pre or perimortem, the CT evidence shows extensive fractures to be consistent with a blunt or blast trauma that would likely have resulted in immediate or rapid death.

Gross and Histologic Diagnoses

- 1). Cranium, rostral skull base, mandible, zygomatic arches, and frontal bones: Fractures, comminuted, severe, closed with variable displacement and hemorrhage (Gross diagnosis).
- 2). Adipose tissue, near mandibular fracture: Congestion, multifocal, mild.
- 3). Spinal cord and peripheral nerve: Hemorrhage, multifocal, mild.

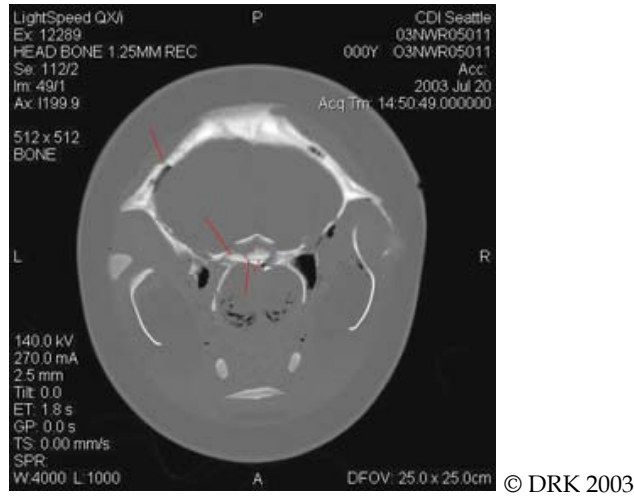


Figure 22 - A 2D cross section of 03NWR05011 demonstrating multiple fractures disrupting the brain case (orange arrows) (Image: D.R. Ketten).

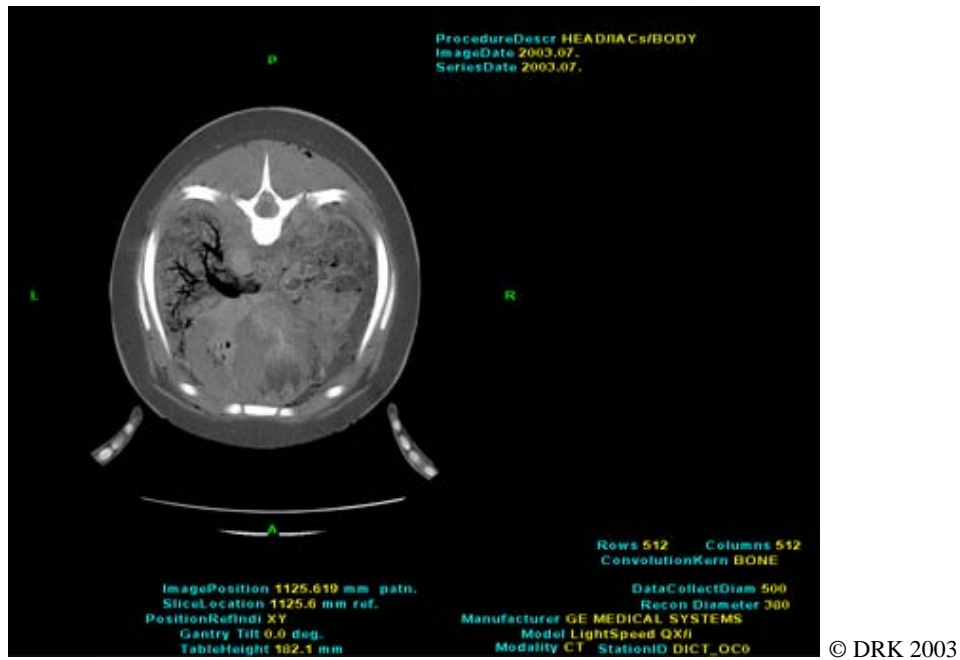


Figure 23 – A CT scan image of 03NWR05011 at the level of the right bronchus demonstrating an ice block (Image: D.R. Ketten).

- 4). Lung: Bronchopneumonia, granulomatous and eosinophilic, multifocal, mild, with few adult nematodes.
- 5). Liver: Cholangiohepatitis, granulomatous and eosinophilic, multifocal, moderate, with biliary ectasia, periductular fibrosis and trematodes.
- 6). Pancreas: Fibrosis, periductular, multifocal, moderate.
- 7). Thymus: Edema, interlobular, multifocal, mild.
- 8). Ear, peribullar (Gross diagnosis): Hemorrhage, moderate, focally extensive with intralesional nematode parasites.
- 9). Ear, intracochlear: Presumptive hemorrhage, mild, multifocal.

Comments and Conclusions

Profound autolysis and freeze artifact hampered histopathology. The most significant findings were the skull and mandibular fractures, with grossly noted hemorrhage within the adjacent tissue. Post mortem changes hindered microscopic assessment of the adjoining fascia and periosteum and hampered precise determination of whether this trauma may have been incurred ante- or postmortem. If inflicted antemortem, the severity of the physical trauma would have been sufficiently severe to account for the loss of this animal. Detection of frank hemorrhage within the lumen of the nares and cochlea, as well as free blood within the trachea, bronchi, esophagus and calverium is suggestive of antemortem blunt trauma that presumably was inflicted by a predator, conspecific, or some other means. The tracheal and esophageal submucosal congestion was likely an agonal or terminal process possibly related to dependent hypostasis. Based on comparison within normal reference values, this animal was in good body condition (Table 3). Aerobic bacterial culture of the liver, thymus, spleen, mesenteric lymph node and urine isolated small numbers of *Enterococcus* spp. In the kidney and spinal cord, there was mixed light growth of *Enterococcus* spp and nonhemolytic *Escherichia coli* and heavy growth of *Clostridium perfringens* from the small intestine and colon (Table 5). No fungi were isolated by special culture of the lung or *Salmonella* spp from the intestine. Negative staining electron microscopy of the conjunctiva disclosed numerous mixed bacteria which are not considered pathologically significant and there were no discernible viral particles. There was insufficient cerebrospinal fluid to assay for canine distemper virus by serology. PCR of pooled lung, lymph node, spleen and brain was negative for Morbillivirus and consensus *Brucella* spp and follow up viral culture on Mabin Darby and Vero cell lines was negative. There is a possibility of reduced pathogen viability associated with post mortem decomposition and freezing. Urinalysis of post mortem urine disclosed dark yellow cloudy urine with a specific gravity of 1025 and protein of 300. No nitrates, ketones, bilirubin, casts, crystals, urobilinogen, mucus, bacteria, fat or white blood cells were detected. There were 1-2 white blood cells, 0-1 red blood cells per high powered field and large numbers of transitional epithelia. Trace mineral and vitamin A analysis of the liver and kidney proved within normal reference limits (Table 6). The hepatobiliary (*Campula* spp), pulmonary (*Halocercus* spp) and gastric (*Anisakis* spp) parasitism is commonly observed in wild porpoises; no parasites were identified by fecal floatation or sedimentation.

3NWR05019

History

This animal was reported stranded on 17 May 2003 at Lagoon Point on Whidbey Island (Figure 1). After examination of the animal at the site, it was wrapped in plastic to prevent further scavenging and moved above the high tide line (Figure 24). The carcass was transferred to the NMML-32 freezer on the evening of 17 May.

Gross Findings

A 138 cm total length, 37.5 kg immature female harbor porpoise was presented dead, 24 July 2003, in moderate body condition. Initial carcass code was coded as a 3, but the internal exam revealed that the deep tissues were in poor post mortem condition (Figure 25). The porpoise was moderately well fleshed. In the right eye, the aqueous humor was diffusely dark red and translucent and a small amount of dark red fluid oozed from the ventral conjunctiva on manipulation of the head. The left eye was absent and the conjunctiva was eroded and irregular (post mortem scavenging). At the level of the right commissure, there was a moderate amount of periosteal edema and congestion of the mandibular body. Sand and debris were found in the nares. Throughout the ventrolateral aspect of the torso, there is extensive fissuring and loss of skin with only small remnants of intact epidermis evident. The left side of the carcass had extensive bird damage.



Figure 24 – Right ventrolateral photograph of porpoise 03NWR05019 at time of initial discovery (17 May 2003) (Photo: S. Berta).

Nervous system: In both the right and left inner ears, there were moderate peribullar accumulations of nematode parasites. Within the rostroventral region of the calverium, immediately below and elevating the periosteum, there was moderate accumulation of dark red subdural fluid.



Figure 25 – Right lateral photograph of porpoise 03NWR05019 at time of necropsy (24 July 2003), demonstrating poor post mortem condition (Photo: B. Hanson).

Respiratory system: At the midlevel of the right lung lobe, moderately deep within the parenchyma, there was a 2x2 cm, pale tan yellow moderately firm nodule that eccentrically entrapped two dilated bronchioles; there was mild to moderate enlargement of the adjoining hilar lymph nodes which were pale grey brown and glistening on sectioned surface. Widely dispersed throughout the lung parenchyma, there were a moderate number of 1mm calcified parasite nodules.

Digestive system: Within the dorsomedial aspect of the hilar region of the liver as well as along the distal limit and to a much lesser extent, midlevel of the right liver lobe, immediately below and slightly elevating the liver capsule, there were small numbers of dilated biliary ductules with moderate numbers of trematode parasites interspersed within variable amounts of black mucoid deposits. There was minimal pancreatic periductular fibrosis and the mesenteric lymphatics were distended with chyme.

There were no apparent lesions within the hemolymphatic, cardiovascular, musculoskeletal, integumentary, urogenital or endocrine systems.

CT Findings

This animal was not scanned.

Gross and Histologic Diagnoses

- 1). Lung: Bronchopneumonia, moderate, multifocal, granulomatous and eosinophilic, subacute with bronchiectasis and many nematode adults and larvae.
- 2). Liver: Cholangiohepatitis, granulomatous and eosinophilic, mild, multifocal, with biliary ectasia and duct hyperplasia.
- 3). Dura, base near cerebellum and left base of cranium: Congestion, moderate, diffuse.
- 4). Peribullar space: Hemorrhage, peri and retrobullar, mild with intralesional nematode parasites (Gross diagnosis).

Comments and Conclusions

Autolysis, freeze artifact and extensive post mortem scavenging prohibited gross evaluation of multiple tissues and hindered microscopic assessment of select tissues.

Subdural and subarachnoid fluids were grossly noted in the brain. The cause of death of this animal was not determined. Due to the extent of post mortem decomposition, lesions consistent with acoustic trauma could not be excluded. The hepatic trematodiasis, colitis and verminous pneumonia were considered low grade and clinically insignificant. The pulmonary nodule noted grossly was an area of verminous pneumonia. The bile duct parasites were most likely *Campula* spp and the lungworms were presumably *Halocercus* spp. Trace mineral analysis of the eye (vitreous humor) fluid revealed calcium levels of 8 mg/dl, magnesium of 10.4 mg/dl, phosphorus of 46 mg/dl and a blood urea nitrogen of 52.1 mg/dl. Although the BUN appeared elevated, the lack of established normal levels for healthy animals confounded interpretation of this data (Table 6). Bacterial culture of the spleen, lumbar lymph node, kidney and liver yielded light mixed growth of *Aeromonas hydrophila* and *Psychrobacter* spp and moderate to heavy growth of these isolates from the lung, brain and spinal cord. No *Salmonella* spp were recovered from the intestine and fungal culture of the lung were negative (Table 5). Based on the extent of post mortem change and lack of attendant inflammatory infiltrate, the heavy growth of *Clostridium perfringens* was attributed to post mortem proliferation. Fecal floatation and sedimentation were negative for parasites and there was no detectable domoic acid within ingesta as determined by SPE and analysis by HPLC.

PCR of pooled lung, lymph node, spleen and brain was negative for Morbillivirus and consensus *Brucella* spp and follow up viral culture on Mabin Darby and Vero cell lines was negative. Trace mineral and vitamin A analysis of the liver and kidney proved within normal reference limits (Table 6).

03NWR05012

History

This specimen was reported on the morning of 20 May 2003 floating off False Bay, San Juan Island (Figure 1), was collected by a whale watch boat operator before noon and delivered to Snug Harbor Marina. The specimen appeared to be in very fresh condition when first observed. Externally, there was no evidence of net entanglement or trauma, except for bleeding from the left eye where birds had pecked away some of the tissue. The carcass was transported around noon to the UWFHL freezer (Figure 26). By mid-afternoon it was returned to the freezer at the Center for Whale Research due to insufficient space at the UWFHL freezer. The evening of 30 June 2003 it was taken to the NMML-4 freezer.

Gross Findings

A 123 cm total length, 30 kg immature male harbor porpoise was presented dead, 23 July 2003, in good nutritional condition. The initial carcass condition was coded as a 2, but the internal exam revealed that the deep tissues were in a fair to moderate post mortem state (Figure 27). The animal was moderately well fleshed (Table 3). Within the dorsal aspect of the head, caudolateral margins of the nares, sub- and intermandibular skin, and bilaterally involving the mandibular fat pads, there was variably extensive congestion of the blubber and subjacent skeletal musculature. The melon was normal and the oral cavity was clear.



Figure 26 – Left lateral photograph of porpoise 03NWR05012 on day of initial report (20 May 2003) (Photo: Center for Whale Research).



Figure 27 – Left lateral photograph of porpoise 03NWR05012 at time of necropsy (23 July 2003) (Photo: B. Hanson).

There was no evidence of deep contusions associated with either mandible. The oropharyngeal mucosa was diffusely dark red. Immediately below the epiglottis and circumferentially involving the goose beak (larynx) mucosa, as well as extending along multiple contiguous laryngeal folds, there was moderate to marked submucosal congestion (Figure 28). Throughout the ventrolateral aspect of the mandible, there were scattered, superficial cutaneous aggregates of diatoms. Within the hypodermis of the perineum, there were multiple granulomas with parasitic tracts and intralesional nematodes. The left eye was punctured and collapsed. Along the distal limit of the right flipper, lower lip and mandible, there were scattered punctate ulcers frequently bound by red brown margins. There were multiple healed rake marks along the right ventral peduncle.

Nervous System: The inner surface of the calvarium was diffusely stained purple to red. There was a large amount of dark red fluid within the cranial cavity. A small amount of dark red fluid was below the meninges and the superficial aspect of the brain was suffused dark red. The dura and the border of bone at the posterior fossae had irregular borders. Both peribullar spaces had substantial burdens of parasites interspersed within moderate amounts of acute hemorrhage. Parasites were also present within the subtemporal region of the cranial vault.

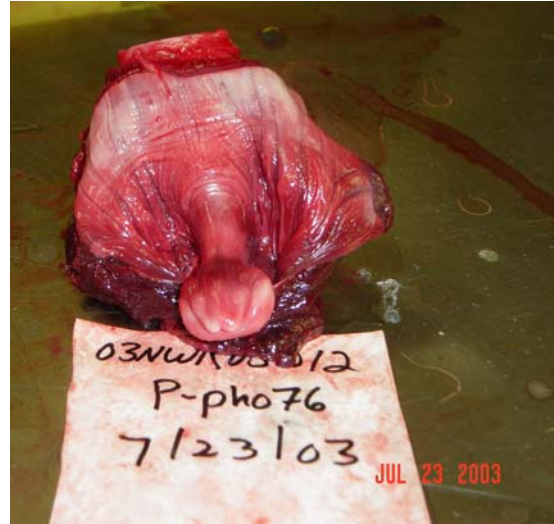
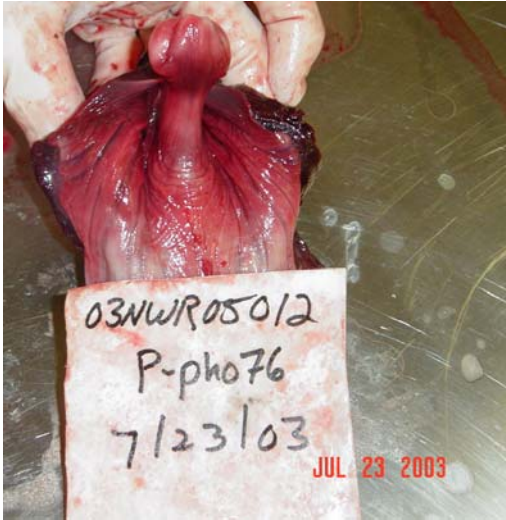
Figure 28 – Two photographs of the larynx of 03NWR05012 demonstrating localized submucosal congestion (Photos: D. Ketten).

Along the lower left margin of the medulla oblongata and spinal cord at the levels of cervical vertebrae 1 and 2, the meninges were overlaid by a small amount of dark red gelatinous material (clot).

Respiratory System: The right lung was diffusely dark red. The left lung was mottled light pink with intervening, slightly depressed and mildly firmer dark red areas. A small amount of dark red froth was within the bronchi and trachea. There were rare 1mm, white, firm, parasitic aggregates widely dispersed throughout the pulmonary parenchyma.

Digestive System: Within the hilar region of the liver there were a small number of dilated bile ducts that contained multiple flukes interspersed within moderate amounts of dark black green tenacious material. There was a moderate amount of green brown ingesta throughout the intestines. A small number of nematodes overlaid or were interdigitated within the mucosa of the forestomachs. There was mild periductular fibrosis noted within the pancreas.

There were no significant lesions within the cardiovascular, musculoskeletal, urogenital, hemolymphatic or endocrine systems.

CT Findings

This animal was in moderate to poor condition. This was a young juvenile, based on size, relatively low skull mineralization and incompletely ossified cranial sutures.

Cranial soft tissues: A majority of the airways and associated spaces were compromised by fluid and foam deposits. The left sinus was opacified and contained both fluid and foam. The blubber layer was thin, but well-defined.

Intracranial/brain: A complex mass was bilaterally juxtaposed to the subtemporal entry

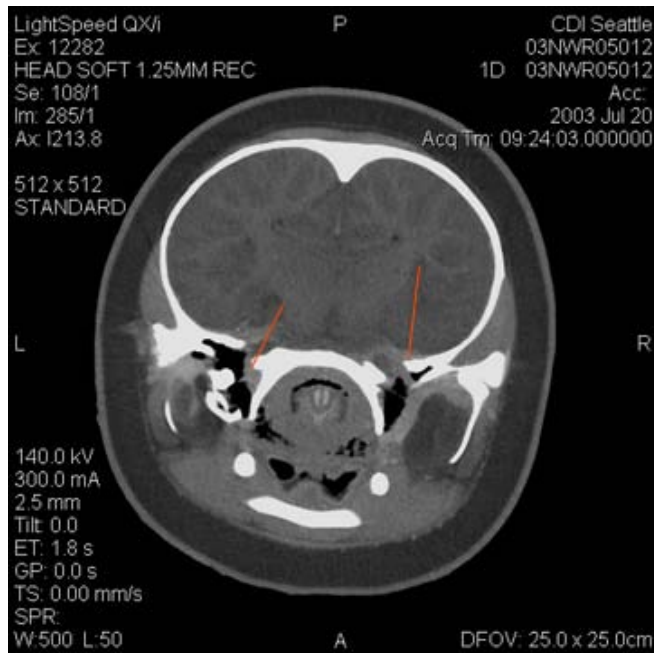


Figure 29 – A CT scan image of 03NWR05012 at the level of the subtemporal entry points of cranial nerves VII and VIII demonstrating a soft tissue mass juxtaposed to the entry points (orange arrows) (Image: D.R. Ketten).

points of cranial nerves VII and VIII (Figure 29). The masses were irregularly shaped and most consistent with a mixture of fats and blood and degenerate parasite aggregates.

Eyes: The right was normal. The left eye was collapsed with an associated, well-organized orbital clot.

Right ear: Aside from some moderate density masses in the medial peribullar region and middle ear, the right peribullar areas were normal. Although the middle ear structures were intact and normal, there were large soft tissue masses suggestive of nematode infestations. The inner ear was normal.

Left ear: The left peribullar areas, were normal with moderate density masses in the medial peribullar region and middle ear. The middle ear contained more soft tissue nematode aggregates than the right ear. The medial ear and inner ear structures were normal.

Post-cranial features: Both lungs were congested and atelectatic with the right more extensively affected at all levels than the left. A soft tissue deposit, with an inconsistent appearance suggestive of a mixture of foamy, sero-sanguinous material, extended from the larynx to the mid trachea.

Gross and Histologic Diagnoses

- 1). Brain, meninges, ventral cerebral hemispheres and diencephalon: Congestion, moderate, diffuse.
- 2). Skin, sub and inter-mandibular; adipose tissue, right upper mandible; spinal cord;

pharynx; and larynx: Congestion, minimal to moderate, focally extensive.

3). Ear, retro and peribullar: Hemorrhage, moderate, bilateral with florid intralesional nematode parasites (Gross diagnosis).

4). Liver: Cholangiohepatitis, granulomatous and eosinophilic, focally extensive, moderate, with biliary ectasia, bile duct hyperplasia, periductular fibrosis and many trematodes.

5). Lung: Pneumonia, granulomatous and eosinophilic, multifocal, mild with few nematodes.

6). Skin, multiple sites: Granulomas, multiple with parasitic tracts and intralesional nematodes.

7). Skin, lip, mandible, and flippers: Ulcers, mild to moderate, multifocal (Gross diagnosis).

8). Ear, peribullar (Gross diagnosis): Hemorrhage, moderate, focally extensive with intralesional nematode parasites.

Comments and Conclusions

Post mortem autolysis, freeze artifact and scavenging impeded gross evaluation of multiple organs and hindered microscopic assessment of selected tissues. The cause of death was not evident. No overt lesions consistent with acoustic trauma were observed. Pronounced congestion throughout the head and oropharyngeal mucosa was presumably due to dependent hypostasis. Based on measurements of blubber and axial skeletal muscle mass, this animal was considered moderately well fleshed (Table 3). The blood clot overlying the spinal cord was attributed to agonal or terminal thrashing at the time of stranding. The peribullar (presumptive *Stenurus* spp) and subcutaneous parasitism due to *Crassicauda* spp was more intense in this individual than examined cohorts. On CT image analysis, the most significant finding was intracranial parasitic invasion from the retrobullar regions through enlarged subtemporal apertures for the cranial nerves VII and VIII. The relatively low bone density of the cranium and incomplete cranial sutures are consistent with an immature animal. The burden of lungworms (presumptive *Halocercus* spp) and liver flukes (*Campula* spp) were not considered pathologically significant. Sections of skin disclosed superficial phytoplankton morphologically consistent with *Navicula* spp. Diatoms have previously been reported in north Pacific porpoises and are generally considered incidental findings (Holmes *et al.*, 1993). Although the precise cause of the cutaneous ulcers was unknown, agonal scavenging was a prime consideration. Aerobic bacterial culture yielded light mixed growth of alpha *Streptococcus* spp and nonhemolytic *Escherichia coli* from the lung and kidney with light growth of alpha *Streptococcus* spp from the mediastinal lymph node. A few colonies of *E. coli* were isolated from the spinal cord and there were no bacteria recovered from the liver or spleen (Table 5). Fungal culture of the lung was negative and no *Salmonella* spp were isolated from the small intestine. The heavy growth of *Clostridium perfringens* was attributed to post mortem proliferation. The extent of autolysis suggested that the remaining isolates were due to post mortem overgrowth. Fecal floatation and sedimentation were negative for parasites. Tissue culture of pooled lung, lymph node and spleen on Mabin Darby and Vero cell lines was negative and PCR for Morbillivirus and *Brucella* spp was unremarkable. Negative staining electron microscopy of the conjunctiva and cutaneous ulcers failed to reveal any discernible pathogens. Ingesta was

processed by strong anion exchange (SAX) solid phase extraction (SPE) cartridges followed by analysis by HPLC with UV detection at 242 nm and was negative for domoic acid. Trace mineral analysis of the liver and kidney were within normal reference limits and interpretation of the eye calcium (5.3 mg/dl), magnesium (5.24 mg/dl), phosphorus (40 mg/dl) and blood urea nitrogen (mg/dl) values is hindered due to the lack of established normal values; in cattle adequate or normal values are calcium: 6.0-7.5 mg/dl, magnesium: 1.90 mg/dl and phosphorus 1.3-3.0 mg/dl (Table 6).

03NWR06005

History

This porpoise was found stranded and collected at 20:00 hr on 2 June 2003 (Figure 30) at Long Beach (Figure 1) and delivered to the NMML-32 freezer on 3 June 2003.

Gross Findings

An adult 146 cm total length, 39 kg reproductively quiescent male harbor porpoise was presented dead, 21 July 2003, in poor body condition. Initial carcass code was coded as a 2, but the internal exam revealed that the deep tissues were in moderate post mortem condition (code 3) (Figure 31). There were minimal visceral and scant nuchal adipose stores and the animal was poorly muscled. Rostral to the melon and randomly within the subcutaneous tissue along the entire length of the torso, there were extensive parasitic tracks, granulomas and nematodes within the hypodermis and, occasionally along deep fascial planes. Throughout the left ventrolateral margin of the pharynx and along the lateral aspect of ribs 2-4 and the cranial third to one-half of the scapula there was multifocally extensive, acute subcutaneous edema and hemorrhage. There were no apparent contusions in the melon. A small amount of red fluid exuded from the oral cavity. There was a small abrasion on the lower mandibular tip.

Respiratory and hemolymphatic systems: At the midlevel of the left lung, deep in the parenchyma, there was a large, 8-10 cm diameter, pale tan yellow moderately firm nodule which peripherally entrapped a small number of markedly ectatic bronchioles that were occluded by dense aggregates of nematode parasites.

Within more normal adjoining parenchyma, there were multiple bronchioles and bronchi that contained variable numbers of nematodes. There was marked enlargement of the regional (mediastinal, hilar and pleural) lymph nodes that on sectioned surface were pale tan yellow, firm, and glistening. Large numbers of nematodes were located within the lumen of the trachea, larynx and nares. There was no foam or blood within the lumen of the nares.

Digestive system: Within the nonglandular compartment of the stomach, there were multiple proliferative and superficially ulcerative nodules and randomly throughout the glandular compartment, there were a small number of punctuate, erosions and ulcerations and trematodes. The small intestine was diffusely inflated with gas and multifocally contained a moderate amount of dark green black, particulate to fluid ingesta. Along the entire length of the large intestine, there was marked smooth muscle hypertrophy and



Figure 30 – Right lateral photograph of 03NWR06005 at stranding site (2 June 2003) (Photo: Cascadia Research Collective).



Figure 31 – Right lateral photograph of porpoise 03NWR06005 at time of necropsy (21 July 2003) (Photo: B. Hanson).

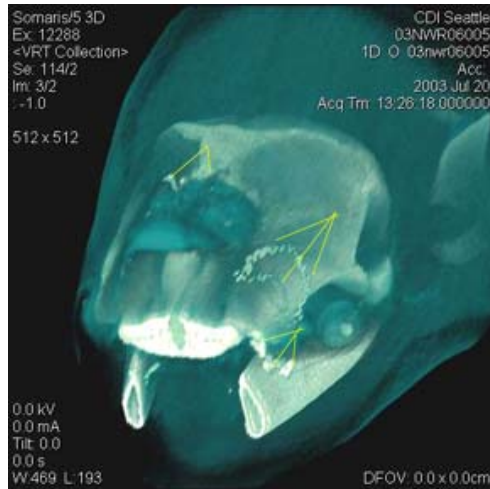
attendant stenosis of the colonic lumen. Within the hilar region of the liver, there were multiple bile ducts that were moderately dilated by trematode parasites and dark green black tenacious material. Pronounced tooth wear was evident throughout the upper and lower arcades.

Nervous system: Bilaterally, within the medial and dorsal peribullar region, there were massive accumulations of nematode parasites (estimate 700 each). Diffusely, the surface of the brain was dark red black and there was variable congestion of the meningeal vasculature.

There were no apparent lesions within the cardiovascular, endocrine, urogenital or musculoskeletal systems.

CT Findings

Cranial soft tissues: The head was intact with normal soft tissue configurations. On the left side there was a convoluted, calcified nematode track that extended nearly 120 mm (Figure 32). There were numerous fibrotic or heavily calcified nodules in almost every major tissue suite of the head. There were substantial cystic deposits in the peri-esophageal tissues as well.



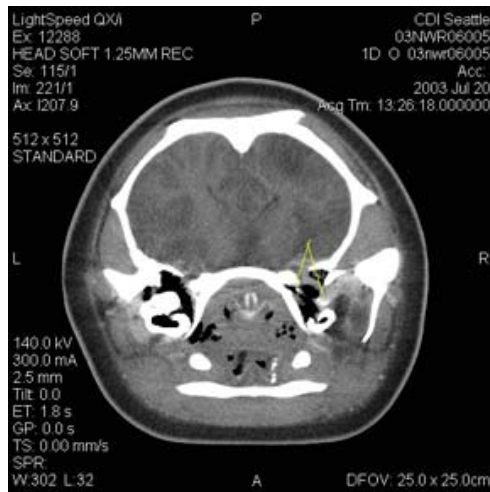
© DRK 2003

Figure 32 – A three-dimensional reconstruction of the head of 03NWR06005 demonstrating the outer surface of the head (blue) with the underlying skull and contoured, calcified parasitic inclusions (white patches with yellow arrows indicating major deposits) (Illustration: D.R. Ketten).

Intracranial/brain: The cranial structures were unremarkable.

Eyes: Both eyes were intact.

Ears: Bilaterally, there was extensive parasitism with substantial calcified inclusions in the peribullar and middle ear tissues (Figure 33). The epithelium of the medial wall of the left retrobullar space was distended. The inner ears were normal bilaterally.



© DRK 2003

Figure 33 – A CT scan image of 03NWR06005 at the level of the peribullar spaces demonstrating a peribullar mass (yellow arrows) with inclusions similar to those seen in Figure 32, as well as calcified cysts in the esophagus (Image: D.R. Ketten).

Post-cranial features: The most remarkable features were extensive calcified parasitic tracts affecting most tissues. There were long, convoluted, calcified threads, several

millimeters in diameter distributed throughout the blubber and musculature of the abdomen. The kidneys were well-defined and contained para-sagittal fibrotic masses. The lungs had extensive clouding bilaterally that paralleled the bronchial tree. This process was more apparent and extensive in the left lung. The right lung airways contained foamy exudate and pooled fluid that extended to the larynx (Figure 34).

Dorsal to the right bronchus of the middle lung lobe, there was a mass effect. Discrete opacified lesions were dispersed throughout both lungs.

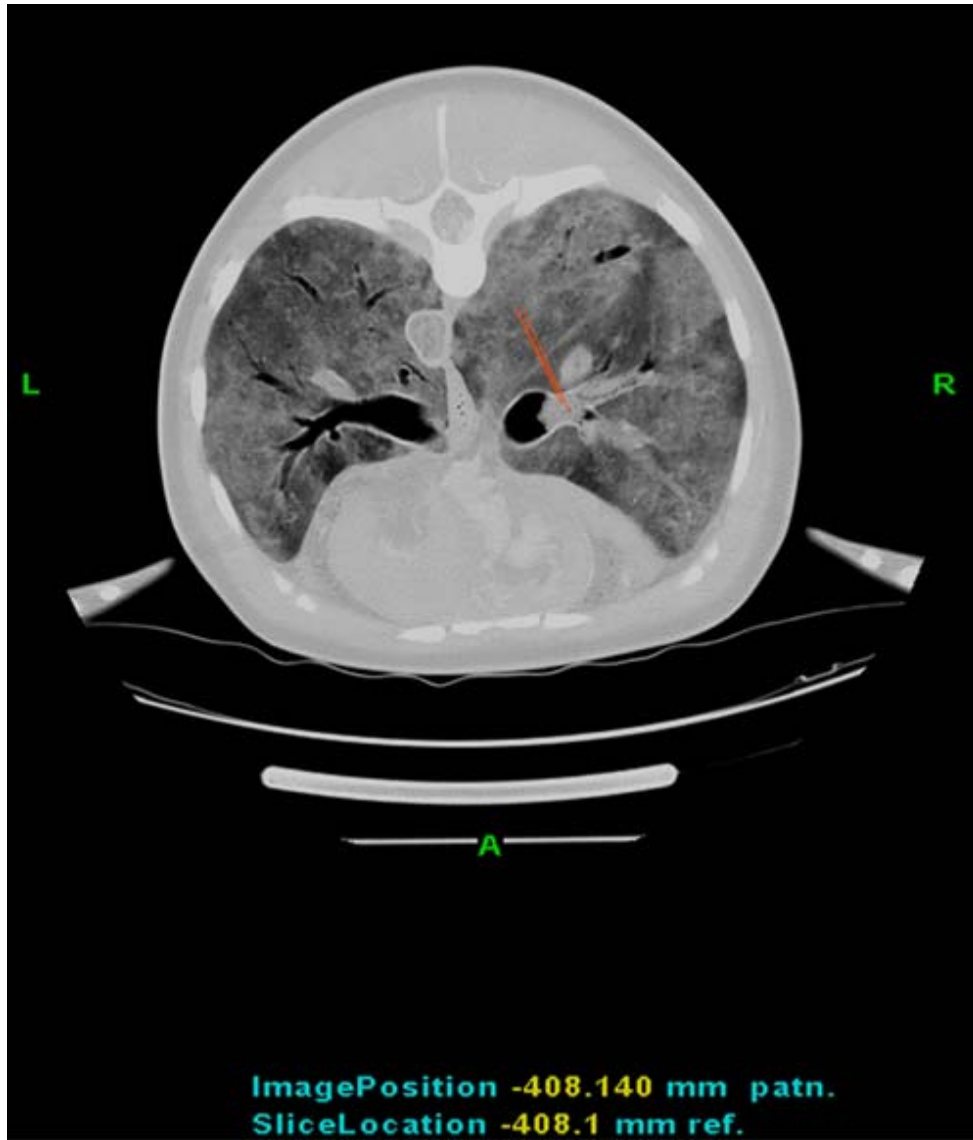Gross and Histologic Diagnoses

- 1). Carcass: Emaciation, marked, generalized (Gross diagnosis).
- 2). Lung: Bronchopneumonia, severe, multifocal, granulomatous and eosinophilic, necrotizing, with bronchiectasis and massive bronchiolar and alveolar accumulation of nematode parasites with florid intralesional fungal hyphae.
- 3). Lymph nodes, mediastinal, hilar and pleural: Lymphadenitis, subacute, multifocal, mild with lymphoid hyperplasia.
- 4). Ear, peribullar: Hemorrhage, marked, focally extensive, with massive accumulation of parasitic nematodes (Gross diagnosis).
- 5). Colon, smooth muscle: Hypertrophy, marked, segmental, with submucosal edema and chronic colitis.
- 6). Skin, generalized: Cellulitis and dermatitis, moderate to marked, multifocal, random, granulomatous chronic with mineral deposition and nematode parasites.
- 7). Liver: Cholangiohepatitis, moderate, multifocal to coalescing, chronic with biliary ductular hyperplasia, ectasia, periductular fibrosis and intraluminal trematodes.

Comments and Conclusions

Postmortem autolysis and freeze artifact hampered histopathology. The most significant lesions were extensive parasitic and mycotic bronchopneumonia, generalized emaciation (Table 3) and colonic smooth muscle hypertrophy. These lesions were profound and cumulatively would have resulted in significant antemortem morbidity and the death of this animal. No overt lesions associated with acoustic trauma were noted. CT image analysis confirmed the extensive calcified parasites particularly within the blubber, fascial planes, retrobullar regions, kidneys, biliary tree, and lungs. Based on experience with previous strandings, this parasitism was considered exceptional, even for this species of odontocetes in which parasites are commonly found. In marine mammals, pulmonary mycotic infections are typically associated with either localized immunosuppression or generalized debility (Reidarson *et al*, 2001). In this case, the emaciation and other disease processes may have been contributory factors. The fungal infection was likely acquired by inhalation of aerosolized conidia and there was no apparent extrapulmonary fungal involvement within the examined tissues. The lung parasites were likely *Halocercus* spp. The regional lymphadenitis and lymphoid hyperplasia were sequelae to the pneumonia. Histopathology of the grossly thickened segments of large intestine disclosed pronounced hypertrophy of the muscularis with variable accumulation of edema fluid and scattered foci of chronic inflammation within the overlying mucosa. Similar changes along varying levels of the small intestine has

been reported in a number of animal species and has been associated with impactions, strictures, stenosis, adhesions, tumors or spastic contractions.



© DRK 2003

Figure 34 – A CT scan image of 03NWR06005 at the level of the lungs demonstrating an accumulation of foamy exudate (orange arrows) and pooled fluid that extended into the larynx (Image: D.R. Ketten).

In this porpoise, there were no apparent predisposing lesions, consequently the hypertrophic change was considered idiopathic. The intensity and distribution of the hypodermal (presumptive *Crassicauda* spp), gastrointestinal (*Anisakis* spp) and peribullar (likely *Stenurus* spp) parasites was enhanced in this relative to other stranded animals and may be secondary to profound debilitation. Fecal floatation and sedimentation were negative for parasites. The subcutaneous edema and hemorrhage noted within the thoracic region was likely due to localized agonal or terminal trauma (blunt impact). Urinalysis disclosed a specific gravity of 1.012, pH of 6.0 and protein of 300. Cytology